



Glaucoma (Eye Disease) and its Associated Diagnosis and Treatment Process: A Schematic Concise Review

**Yash Srivastav ^{a++*}, Bushra Taj ^b, Jaya Singh ^c,
Sandhya Yadav ^c and Mohd. Imtiyaz Ahmad ^a**

^a Azad Institute of Pharmacy & Research, Lucknow, U.P, India.

^b Ashoka Institute of Technology and Management, Varanasi, U.P, India.

^c Tahira Institute of Medical Science, Gorakhpur, U.P, India.

Authors' contributions

This work was carried out in collaboration among all authors. All authors read and approved the final manuscript.

Article Information

DOI: 10.9734/OR/2024/v19i3425

Open Peer Review History:

This journal follows the Advanced Open Peer Review policy. Identity of the Reviewers, Editor(s) and additional Reviewers, peer review comments, different versions of the manuscript, comments of the editors, etc are available here: <https://www.sdiarticle5.com/review-history/116423>

Review Article

Received: 04/03/2024
Accepted: 08/05/2024
Published: 10/05/2024

ABSTRACT

A class of eye conditions known as glaucoma can result in blindness and visual loss by harming the optic nerve, a nerve located at the back of the eye. You might not notice the symptoms at first because they can appear so slowly. A thorough dilated eye exam is the only way to determine if you have glaucoma. While there is no known cure for glaucoma, vision protection and damage can frequently be stopped with early intervention. Primary open-angle and angle-closure glaucoma, as well as secondary open and angle-closure glaucoma, are the four main types of adult glaucoma. Prescription eye drops are the most popular form of treatment for glaucoma. They function by reducing intraocular pressure and shielding your optic nerve from harm. Although these eye drops cannot reverse vision loss or treat glaucoma, they can prevent glaucoma from worsening. Prostaglandins are one type of prescription eye drop medication. By increasing the fluid's outflow

⁺⁺ Master of Pharmacy in Pharmaceuticals and Assistant Professor;

^{*}Corresponding author: E-mail: neelashsrv76@gmail.com;

from your eye, they aid in lowering intraocular pressure. Latanoprost (Xalatan), Travoprost (Travatan Z), Tafluprost (Zioptan), Bimatoprost (Lumigan), and Latanoprostene bunod (Vyzulta) are among the medications in this category. Alpha-adrenergic agonists, such as brimonidine (Altagan P) or Qoliana (lopidine, apraclonidine) Beta-blockers such as Betimol, Istalol, Timoptic (timolol), and Betoptic (betaxolol) Inhibitors of carbonic anhydrases, such as Azopt (brinzolamide) and Trusopt (dorzolamide). In this review study, we discuss the aetiology, epidemiology, current management, and pathophysiology of glaucoma.

Keywords: Glaucoma; epidemiology; etiology; pathophysiology; treatments.

1. INTRODUCTION

Three main phases may be distinguished in the history of the conditions currently grouped under the word "glaucoma." First, there is the early era between 400 BC and 1600 AD, when "glaucoma" was used to describe a broad category of blinding eye disorders without the distinctions that historians can now identify. Between the start of the 17th century and the middle of the 19th century, written books started to identify the individual and combined cardinal indications of glaucoma. The third historical period spans from the invention of the ophthalmoscope in 1854 to the present. In medicine, glaucoma has been understood since antiquity. According to Hippocrates, "glaukoseis" is a type of blindness that affects the eye. The link between elevated ocular stress and glaucoma was initially established by the English ophthalmologist Banister. The crucial development of the ophthalmoscope by von Helmholtz in 1850 allowed for the diagnosis of fundus glaucomatous alterations. Donders identified "Glaukoma simplex," the condition he named after discovering in 1862 that elevated intraocular pressure was linked to blindness. The development of the perimeter and tonometer, as well as the usage of cocaine, contributed to further advancements in glaucoma diagnosis. Von Graefe performed the first iridectomy, a successful surgical treatment for glaucoma, in 1856. With the discovery of pilocarpine in 1875, drug therapy got underway [1,2]. A neurological disease affecting the eyes called glaucoma is linked to elevated intraocular pressure (IOP). Patients may eventually lose their ability to see and may perhaps lose their sight entirely if treatment is not received. It ranks as the second most common cause of blindness worldwide.

"A definition of glaucoma is a disorder that results in progressive neuropathy in the visual field and is characterized by structural alterations to the optic disk or optic nerve head. The patient's visual field may shift functionally as a

result of this. Range of disorders of the Eyes that can result in blindness. The nerve that connects the eye to the brain is harmed in all forms of glaucoma, typically as a result of elevated intraocular pressure. Other than gradual vision loss, open-angle glaucoma, the most prevalent kind of the condition, frequently exhibits no symptoms. Despite being uncommon, angle-closure glaucoma is a medical emergency with symptoms that include nausea and abrupt vision disruption in addition to ocular pain" [3]. "Glaucoma can be classified into two main categories: primary and secondary. Both of these have two major subgroups based on the underlying anatomy and pathophysiology: angle-closure and open-angle.

Both open-angle and closed-angle glaucoma without a known cause are referred to as primary or idiopathic glaucoma, whereas secondary glaucoma has a known cause—an elevated intraocular pressure that damages the optic nerve. There are three types of open-angle glaucoma: normal-tension glaucoma (NTG), secondary open-angle glaucoma, and primary open-angle glaucoma (POAG). Secondary open-angle glaucoma is characterized by elevated IOP and/or optic neuropathy, while POAG is characterized by an increased IOP with progression of the optic nerve; NTG is characterized by a normal IOP with progression and optic neuropathy. Primary open-angle glaucoma (POAG) is thought to impact 57.5 million people globally. A higher risk of glaucoma is associated with age over 60, family members of people already diagnosed with the condition, steroid users, diabetics, high myopia, hypertension, central corneal thickness less than 5 mm, and ocular trauma. It is projected that 76 million people will have glaucoma by 2020, and by 2040, the figure is likely to rise to 111.8 million" [4]. "Based on epidemiological studies involving individuals 40 years of age and older, the prevalence of glaucoma in Indians has been estimated to be between 2.7% and 4.3%. By 2040, 27.8 million more people in Asia are

expected to suffer from glaucoma; China and India will bear the greatest part of this burden. Glaucoma is one of the main causes of permanent blindness in India, accounting for 5.5% of all cases of blindness and 1.2 million cases of blindness" [5].

2. EPIDEMIOLOGY

An estimated 60 million individuals worldwide suffer from visual neuropathy as a result of glaucoma. The open-angle form is most common among the African population. Those who identify as African-descent are up to 15 times more likely than people from other demographic categories to become blind from open-angle glaucoma. The Inuit people have the highest frequency of angle closure, and studies have indicated that women are more affected than men, as well as people of Asian descent, who typically have a shallower anterior chamber. Japanese inhabitants are most commonly affected by the normal-tension kind of glaucoma. "Age is a significant risk factor for the ongoing loss of retinal ganglion cells in all types. An additional risk factor for developing glaucoma is having a primary relative (mother, father, brother, sister, or children) with a family history of the condition; medical conditions like diabetes, hypertension, and heart disease; eye trauma; anatomical differences like thinner corneas; a history of retinal detachment; eye tumours or inflammation; and long-term use of corticosteroids" [6,7].

3. SYMPTOMS AND SIGNS

Increased intraocular pressure: the balance between aqueous production inside the eye and aqueous drainage out of the eye through the trabecular meshwork determines the intraocular pressure. Around 2 l of aqueous are produced by each typical eye each minute, or around 70 l throughout a lifetime. The intraocular pressure should be between 10 and 21 mm Hg, but in hypotony, it can drop as low as 0 mm Hg, and in some glaucomas, it can rise as high as 70 mm Hg. Numerous variables, such as the pressure and the stage of glaucoma, determine how quickly increased intraocular pressure damages the optic nerve.

Pressures between 20 and 30 mmHg often cause damage over some years, whereas pressures between 40 and 50 mmHg can cause retinovascular occlusion and fast sight loss. Hazy corneas and haloes surrounding lights The

endothelial cells' constant extrusion of fluid keeps the cornea clear. Acute closed-angle glaucoma, a rapid rise in intraocular pressure, causes the cornea to become waterlogged, impairing vision and producing haloes around lights that resemble frosted glass. Anguish Pain is not a sign of glaucoma until the pressure is quite high if the rise in pressure is gradual. The main hallmark of open-angle glaucoma is not pain. Loss of visual field Damage to the retinal nerve fibres is caused by pressure on the nerve fibres and persistent ischaemia at the optic nerve head. This typically results in distinctive patterns of field loss (arcuate scotoma). Nevertheless, the patient initially does not detect the abnormality because centre vision is spared. Even in the last stages of glaucomatous field loss, vision can still be 6/6 (tunnel vision). Variations in the optic disc designate where the retinal nerve fibres leave the eye. An extended increase in intraocular pressure causes the nerve fibres to atrophy, resulting in the cupped, pale optic disc that is indicative of chronic glaucoma. Obstruction of the veins Increases the risk of retinal venous occlusion can result from elevated intraocular pressure, which can block blood flow in the venous system [8].

4. ETIOLOGY

NTG, also known as normal pressure glaucoma or low tension glaucoma, is characterized by optic disc fractures and cupping, with an intraocular pressure of less than 21 mmHg. Although the results of NTG are commonly thought to be comparable to those of POAG, its aetiology and damage mechanisms are distinct from those of POAG with high IOP. According to current NTG theory, retinal injury may result from a loss of perfusion; observations of disturbed ocular blood flow (OBF) suggest that retinal venous pressure (RVP) may have increased, damaging the axons of the retinal ganglion cells that make up the optic nerve [9]. Although the precise cause of glaucoma is currently unknown, most cases of POAG exhibit a definite link with higher ocular pressures. The main symptom of open-angle glaucoma is usually gradual, painless damage to the optic nerve, which is believed to be caused by the eye's drainage system failing. Resistance to aqueous humour drainage in glaucoma typically begins at the juxtacanalicular trabecular meshwork, which is the inner wall of Schlemm's canal. The steady rise of intraocular pressure (IOP) and the characteristic damage pattern to the nerve fibre layer of the optic nerve ganglion cell are caused by the decreased

outflow facility and increased resistance to the outflow of aqueous. Another explanation is that mild ischemia damage results from decreased blood supply to the optic nerve fibres due to elevated IOP. In any case, increased intraocular pressure (IOP) values are frequently observed in POAG patients, and these readings appear to be correlated with distinct patterns of optic nerve injury. As the condition worsens, both eyes gradually lose their peripheral vision, which, if undiagnosed or untreated, can eventually result in loss of central vision. People who are impacted by this pattern of loss do not become aware of any changes in their vision until the loss progresses and begins to impair central vision [6]. Juvenile open-angle glaucoma and low-tension/normal-tension glaucoma are two subtypes of open-angle glaucoma. Patients with juvenile open-angle glaucoma often range in age from five to thirty-five. It is rare and is usually discovered later in the course of the disease due to its early but progressive elevation of IOP. Patients frequently have ocular pressures higher than 30 mm Hg when they first arrive. Though it affects a younger patient population, juvenile open-angle is considered to follow the same path of elevated IOP leading to optic neuropathy as POAG. The peripheral vision field loss and optic disc cupping that characterize POAG are also present in low-tension or normal-tension glaucoma, although the IOP values are consistently less than 21 mm Hg. Atherosclerosis/vascular insufficiency-related intermittent ischemia change or an unusually sensitive optic nerve are two possible theories. Vasospastic disorders including migraines, Raynaud phenomenon, autoimmune diseases, ischemic vascular diseases, and coagulopathies seem to be more common in these patients, which may indicate a role for vascular autoregulatory dysfunction in the pathophysiology of the disease. In comparison to those with open-angle type, normal-tension patients also frequently experience haemorrhages in the nerve fibre layer and have a smaller neuroretinal margin inferiorly and inferotemporal. Open-angle visual field defects are not the traditional arcuate scotoma pattern; instead, they are more focused, deeper, and closer to fixation [10,11]. Angle-closure glaucoma may develop as a result of another factor. Lens subluxation in Marfan's syndrome is one such reason. Acute pupillary obstruction may result from the lens shifting into the pupil or anterior chamber. Because of ciliary processes that are extended or positioned anteriorly, the plateau iris can also result in chronic angle closure and

acute pupillary block. These conditions push the iris's edges forward. The corneal endothelium is uneven in iridocorneal endothelial syndrome and has the potential to migrate into the peripheral iris and trabecular meshwork. This results in a contraction that raises the anterior synechiae in the periphery, closing the angle and blocking outflow. By generating a fibrovascular membrane that flattens and pushes the iris anteriorly, neovascularization can result in complete synechial closure of the angle [12–17]. Like the open-angle form of glaucoma, secondary open-angle type glaucoma is caused by injury, eye disease, and infrequently, eye surgery that raises intraocular pressure and damages the optic nerve. Laser surgery can induce pigment release, inflammatory cells, debris, and mechanical deformation that obstructs the trabecular meshwork and raises intraocular pressure. This is one mechanism of secondary open-angle glaucoma. The most frequent cause of the secondary open-angle type is neovascularization-causing illnesses. Either the outflow tracts can be physically blocked by neovascularization. When flaky material peels off the outer lens capsule and gathers in the angle, obstructing the trabecular meshwork and increasing eye pressure, this is known as the pseudoexfoliative type. The pigmentary type is similar to the exfoliative type, but in usually myopic, or nearsighted, eyes, the debris are pigment granules from the back of the iris that break off and clog the trabecular meshwork because they come into touch with the peripheral lens capsule and zonules. Due to the buildup of glycosaminoglycans in the meshwork pores and the activation of glucocorticoid receptors on trabecular meshwork cells, steroids can cause secondary glaucoma by increasing outflow resistance. Steroids also inhibit phagocytic activity, which increases the expression of extracellular matrix proteins and reduces the clearance of debris deposition from the meshwork. An improper communication between the carotid artery and cavernous sinus is brought on by a carotid-cavernous fistula. Elevated episcleral venous pressure results from increased venous engorgement and arterial flow caused by this. Additionally, it results in the enlargement of the optic disc and dilatation of the retinal veins, which might harm optic nerve fibres at the same time. It has been observed that glaucomatous damage to the optic nerve over time might result from recurrent acute incidents of elevated intraocular pressure that resolve without therapy. This condition is known as a glaucomatocyclitic crisis [18–22].

5. PATHOPHYSIOLOGY

Although glaucoma genes have been categorized, they only make up a minor fraction of the disease. Recent advances in genomic and proteomic technology have boosted the use of genetic techniques. While primary angle closure glaucoma (PACG) can be acute or chronic and is characterized by papillary block, angle crowding, or both, primary open-angle glaucoma (POAG) is a progressive optic neuropathy linked to optic disc cupping and glaucomatous visual field abnormalities. Even though the cause of glaucoma is uncertain, it has been suggested that a vascular component plays a role in the disease's aetiology. Damage to the glaucoma is caused by a first insult and a series of secondary events that follow. The progression of vision loss in glaucoma begins with a paramacular lesion in the temporal field and moves along the arcuate pattern created by the retinal vasculature and axons of retinal ganglionic cells (RGCs). Axon damage is primarily caused by several interrelated causes that travel from the optic nerve head (ONH) to the retina, including ischaemia at the optic nerve head located after the lamina. Next, there is secondary damage that progresses more slowly and affects the nearby neurons. These secondary lesions could develop if the neurovascular connection is disrupted or if ocular perfusion pressure drops below the lower limit of autoregulation. The first-line medications for treating glaucoma are prostaglandins and beta-blockers because they lower intraocular pressure (IOP) by promoting the non-conventional outflow of aqueous humour and lowering the production of aqueous humour. The

second-line treatments are α_2 -agonists and carbonic anhydrase inhibitors [23]. As of right now, screening pressure results of more than 21 mm Hg are regarded as abnormally high and suggest the possibility of future glaucomatous nerve injury. It can be challenging to determine, though, whether patients are momentarily raising their blood pressure throughout the day, doing harm without being noticed by screening. This contributes to the fact that elevated screening pressure is not necessary for the diagnosis of glaucoma, but rather can merely be a risk factor for the condition's development. IOP diurnal pressure monitoring could be useful in identifying this patient group. In addition to having systemic vascular diseases such as migraines, sleep apnea, carotid artery disease, and greater than usual variations in blood pressure overnight, patients with normal-tension glaucoma also frequently experience these symptoms. This trabecular meshwork drainage pathway is blocked in acute angle-closure glaucoma due to either the iris being forced forward by fibrous tissue or being pushed forward by pressure, such as an anteriorly displaced lens. The most common cause is a pupillary block, in which the iris seals off the trabecular meshwork obstructing the aqueous outflow, dilates to mid-position, and bows anteriorly in response to contact with the lens. As was already established, there are several ways that secondary glaucoma can develop. These include neovascularization or surgery that obstructs the outflow tracts, which raises intraocular pressure, and, if left untreated, linked glaucomatous optic nerve damage [24–26].

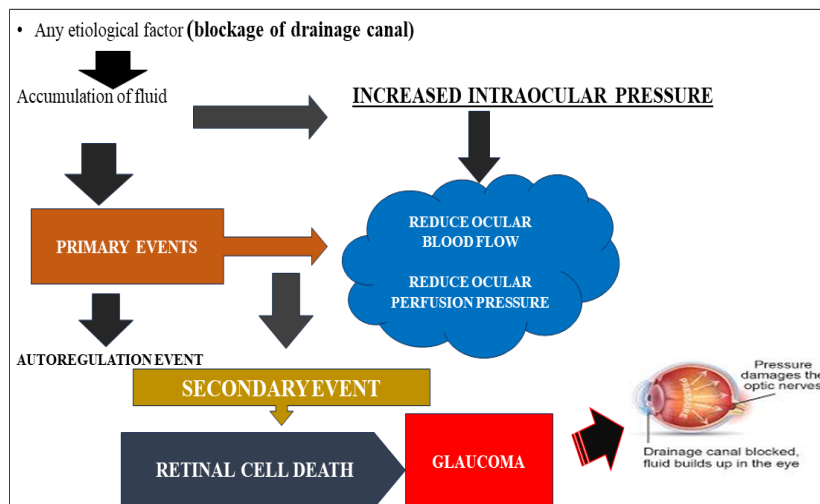


Fig. 1. Glaucoma's pathophysiology [23]

6. DIAGNOSIS

Fundoscopy examination, visual field testing, tonometry, optical coherence tomography, and gonioscopy are used as the basis for evaluation. Pachymetry, which measures corneal thickness, visual acuity, which determines whether the vision is damaged, and retinal scans, which track any progressive alterations in the retinal nerve fibre layer, are other useful tests. Based on the above-mentioned testing modalities, glaucoma is diagnosed based on distinctive clinical signs of progressive optic neuropathy or visual field abnormalities. The diagnosis of glaucoma cannot be made with a single gold standard test. To correctly diagnose and stage glaucoma, healthcare providers need to be aware of the distinctive look of the optic nerve, identify risk factors, and compile the findings of ancillary testing. As of right now, the American Academy of Ophthalmology advises individuals who have glaucoma risk factors to get routine, thorough eye exams on a case-by-case basis, taking into account their age, race, risk factors, and family history. It is necessary to rule out other medical conditions that can produce visual neuropathy to diagnose primary open-angle glaucoma. A prior ischemic optic neuropathy, optic atrophy, and compressive non-glaucomatous optic neuropathy are other possible diagnoses to consider. These conditions can result in similar patterns of visual field loss and, in rare cases, "pseudo-cupping" of the optic nerve. Gonioscopy should be used to assess anterior chamber width and closure in the event of high intraocular pressure (IOP) or

classic glaucomatous optic nerve abnormalities. In addition, it's critical to assess for the subtle symptoms of the many forms of secondary glaucoma, look over the medication list for potential odd drug reactions or steroid responses, and obtain a complete medical history of previous eye damage and surgery [27]. In addition to iritis, traumatic hyphema, conjunctivitis, episcleritis, migraine, cluster headache, corneal abrasion, endophthalmitis, orbital compartment syndrome, corneal ulcer, periorbital infections, and infectious keratitis are other possible diagnoses to consider with an acute presentation such as that of acute angle-closure. The clinician can narrow the differential and make arrangements for the proper evaluation and referral with the help of a thorough history and slit-lamp examination [28–30].

7. OPTIONS FOR TREATING GLAUCOMA

The course of treatment for glaucoma depends on its particular kind and severity. Currently, no cure can undo any already-acquired vision loss; treatments can only work to stop more harm and loss of eyesight. Monitoring the development of the disease can be aided by mapping vision loss and performing visual field testing. Eye drops: When latanoprost was introduced to the glaucoma market in 1998, PGAs were the final class of medications to be offered. Twenty years later, the rho kinase inhibitor netarsudil 0.02% was approved by the Food and Drug Administration. By increasing

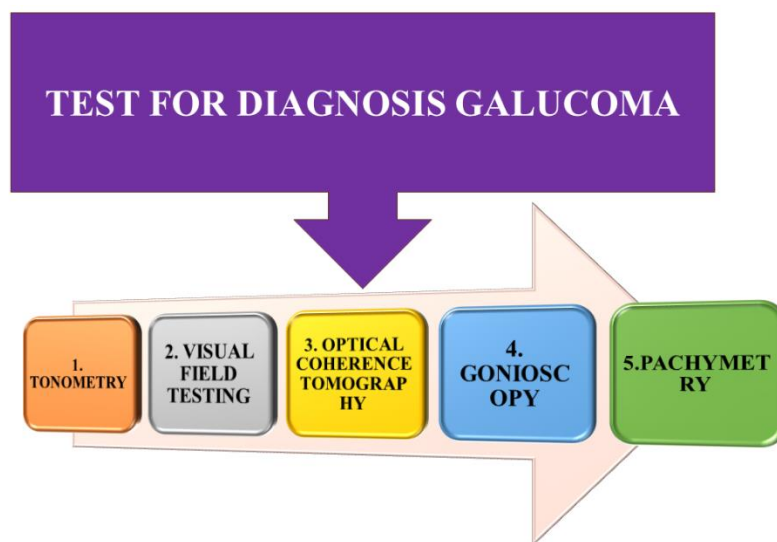


Fig. 2. Diagnosis of Glaucoma

trabecular outflow, decreasing aqueous humor secretion, and perhaps lowering episcleral venous pressure, netarsudil, when taken regularly, decreases intraocular pressure. No other IOP-lowering medication on the market today lowers IOP by acting on the trabecular meshwork, except the infrequently used miotics. Although netarsudil is not as effective as PGAs, it is still a viable second-line agent that can be used either alone or in conjunction with PGAs. Despite having a higher rate of conjunctival hyperaemia than timolol, it is safer for the body overall. Late in 2017, latanoprostene bunod was also approved by the Food and Drug Administration. It is a PGA that donates nitric oxide. Aqueous outflow via the trabecular meshwork is improved by nitric oxide. In terms of effectiveness and safety profile, latanoprostene bunod is superior to latanoprost. medication delivery: Phase 1 and 2 clinical studies are being conducted on several innovative medication delivery technologies. The objective is to enhance medication delivery to the right receptors, which will increase adherence, boost efficacy, and lessen the negative effects of the current topical IOP-lowering medications. Subconjunctival injections and implants, intracameral implants, conjunctival ocular ring inserts, and drug-eluting punctal plugs are all under investigation. This is a promising field that will enhance many patients' treatment outcomes [31]. For the sake of completeness, the osmotic agents (mannitol, glycerin, and urea) are included. These powerful medicines are employed in two contexts: either as a preventive measure against expulsive suprachoroidal haemorrhage before incisional surgery in cases where the eye may be open for an extended time or in the acute therapy of increased IOP (e.g., acute angle closure glaucoma). According to conventional wisdom, these medications work by contracting the vitreous by raising the osmotic gradient between the plasma and the eye, which lowers the intraocular pressure by decreasing the volume in the eye [31]. First-line treatment for open-angle glaucoma often involves lowering ocular pressure with medicines. Prostaglandin analogues, beta-blockers, alpha-2 agonists, carbonic anhydrase inhibitors, miotic agents, and, more recently, rho-kinase inhibitors and nitric-oxide donating drugs are among the pharmaceutical types. In certain situations, laser trabeculoplasty is also the main course of treatment. Procedures like as laser trabeculoplasty, trabeculectomy, insertion of a drainage valve/tube shunt, or laser treatment to the ciliary body to diminish aqueous production

can be utilized to establish better control of IOP if medicinal management is not successful. For people with mild-to-moderate glaucoma, there is also an emerging option called minimally invasive glaucoma surgery (MIGS). In comparison to traditional trabeculectomy and tube shunts, MIGS has a better overall safety profile and a quicker recovery period, and it is successful in lowering IOP to the mid-high teens. The idea that MIGS placement can minimize the quantity of blood pressure-lowering drugs needed to sustain desired IOP levels is further supported by studies. In addition to treating any potential underlying medical issues, medicines to lower intraocular pressure can be used to treat normal-tension glaucoma. Prostaglandin analogues, alpha-2 agonists, carbonic anhydrase inhibitors, and miotics are among the medications. Because of concerns about reduced perfusion of the optic nerve head, particularly in light of the possible aggravation of the early morning blood pressure nadir, beta-blockers are contentious. If vision loss progresses further and medical therapy is ineffective, laser trabeculoplasty or filtration surgery may be used. Patients with normal-tension glaucoma have been demonstrated to halt or stabilize their field loss following a 30% decrease in intraocular pressure (IOP) in the Collaborative Normal-tension Glaucoma study. Angle-closure needs to be handled like an emergency. This is due to the possibility that pressures could be high enough to result in retinal vascular blockage, ischemic nerve injury, or glaucomatous optic nerve damage. To lower eye pressure as soon as possible, patients can take medication, however laser peripheral iridotomy is typically necessary. To alleviate pupillary block and balance the pressure gradient between the anterior and posterior chambers, this laser makes a tiny hole in the iris. This opens the anterior chamber drainage angle and resolves the iris bombe. Laser rhinoplasty and, less frequently, laser phalloplasty can be used to flatten the peripheral iris. It is crucial to have a follow-up gonioscopy to confirm that the angle has reopened and to determine the percentage of the angle with peripheral anterior synechia from the acute or previous subacute attacks. Decreased intraocular pressure is not always a sign that the angle has reopened because the ciliary body can experience ischemic damage during an attack and have decreased production for a few weeks. Patients should be evaluated for gonioscopy and, if narrow, preventive iridotomy in the opposite eye once the acute crisis has been managed, as they are highly susceptible to

an attack in the contralateral eye. The underlying cause of secondary glaucoma should be addressed to treat the condition, and depending on that cause, medicine to lower intraocular pressure may need to be added [32–35].

8. DISCUSSION AND CONCLUSION

Our review articles begin with an introduction to glaucoma, including its various causes, epidemiology, pathophysiology, and alternative therapy. According to our findings, medications do indeed treat. Further randomized controlled trials are needed to address the treatment of glaucoma. In the future, we would like to do a preliminary investigation of glaucoma. With the help of our colleagues, future counselling-based research in our country or state will assess the physical and mental health of patients and produce more accurate data on glaucoma and its treatment.

CONSENT AND ETHICAL APPROVAL

It is not applicable.

ACKNOWLEDGEMENT

The authors would like to thank, Azad Institute of Pharmacy & Research (AIPR), Lucknow, U.P, India, Lucknow, Uttar Pradesh, India for extending their facilities.

COMPETING INTERESTS

Authors have declared that no competing interests exist.

REFERENCES

1. Grewe R. Zur Geschichte des Glaukoms [The history of glaucoma]. *Klin Monbl Augenheilkd.* 1986;188(2):167–9.
2. Leffler CT, Schwartz SG, Hadi TM, Salman A, Vasuki V. The early history of glaucoma: The glaucous eye (800 BC to 1050 AD). *Clin Ophthalmol.* 2015;9:207–15.
3. Schellack N. Glaucoma: A brief review. 2016;(January 2015).
4. Allison K, Patel D, Alabi O. Epidemiology of Glaucoma: The Past, Present, and Predictions for the Future. *Cureus.* 2020;12(11).
5. Rewri P. Towards better management of glaucoma in India. *Indian J Ophthalmol.* 2023;71(3):686–8.
6. Jonas JB, Aung T, Bourne RR, Bron AM, Ritch R, Panda-jonas S. *Seminar Glaucoma.* 2017;390:83–93.
7. Bourne RRA, Stevens GA, White RA, Smith JL, Flaxman SR, Price H, et al. Causes of vision loss worldwide, 1990 – 2010: A systematic analysis. 2012;339–49.
8. Khaw PT, Elkington AR. Glaucoma—1: Diagnosis. *Bmj.* 2004;328(7431):97.
9. George A, Yanan L, Dominic MKL. Normal tension glaucoma: Prevalence, aetiology and treatment. *J Clin Res Ophthalmol.* 2021;8:023–8.
10. Turalba A V., Chen TC. Clinical and genetic characteristics of primary juvenile-onset open-angle glaucoma (JOAG). *Semin Ophthalmol.* 2008;23(1):19–25.
11. Drance S, Anderson DR SM. Collaborative Normal-Tension Glaucoma Study Group. Risk factors for progression of visual field abnormalities in normal-tension glaucoma. *Am J Ophthalmol.* 2001;131:699–708.
12. Sivak-Callcott JA, O'Day DM, Gass JDM, Tsai JC. Evidence-based recommendations for the diagnosis and treatment of neovascular glaucoma. *Ophthalmology.* 2001;108(10):1767–76.
13. Muir MGK, Hitchings RA. Syndrome. 2015;
14. Kiuchi Y, Kanamoto T, Nakamura T. Double hump sign in indentation gonioscopy is correlated with the presence of plateau iris configuration regardless of patent iridotomy. *J Glaucoma.* 2009;18(2):161–4.
15. Izquierdo NJ, Traboulsi EI, Enger C, Maumenee IH, Walton DS, Ferry AP, et al. Glaucoma in the Marfan syndrome. *Trans Am Ophthalmol Soc.* 1992;90:111–22.
16. Perez RN, Phelps CD, Burton TC. Angioclusion glaucoma following scleral buckling operations. *Trans Sect Ophthalmol Am Acad Ophthalmol Otolaryngol.* 1976;81(2):247–52.
17. Aminlari A, East M, Wei W, Quillen D. Topiramate Induced Acute Angle Closure Glaucoma. *Open Ophthalmol J.* 2008; 2(1):46–7.
18. Calafiore S, Perdicchi A, Scuderi G, Contestabile MT, Abdolrahimzadeh S, Recupero SM. Glaucoma management in carotid cavernous fistula. *Case Rep Ophthalmol.* 2016;7(2):296–302.
19. Plateroti P, Plateroti AM, Abdolrahimzadeh S, Scuderi G. Pseudoexfoliation syndrome and pseudoexfoliation glaucoma: A review

- of the literature with updates on surgical management. J Ophthalmol. 2015 ;2015.
20. Posner A, Schlossman A. Further observations on the syndrome of glaucomatocyclitic crises. Trans - Am Acad Ophthalmol Otolaryngol Am Acad Ophthalmol Otolaryngol. 1953;57(4):531–6.
 21. Roll P, Benedikt O. [Electronmicroscopic studies of the trabecular meshwork in corticosteroid glaucoma]. Klin Monbl Augenheilkd. 1979 Mar;174(3):421–8.
 22. Choong YF, Irfan S, Menage MJ. Acute angle closure glaucoma: An evaluation of a protocol for acute treatment. Eye. 1999;13(5):613–6.
 23. Piplani P, Aggarwal D, Abbhi V, Saini L. Prostaglandin analogues: A current treatment option for glaucoma. Med Chem Res. 2016;25(6):1031–48.
 24. Arora T, Bali SJ, Arora V, Wadhvani M, Panda A, Dada T. Diurnal versus office-hour intraocular pressure fluctuation in primary adult-onset glaucoma. J Optom [Internet]. 2015;8(4): 239–43. Available: <http://dx.doi.org/10.1016/j.optom.2014.05.005>
 25. Drance SM, Sweeney VP, Morgan RW, Feldman F. Factors involved in the production of low tension glaucoma. Can J Ophthalmol. 1974 Oct;9(4):399–403.
 26. Levene RZ. Low tension glaucoma: A critical review and new material. Surv Ophthalmol. 1980;24(6):621–64.
 27. Dietze J, Blair K, Havens SJ. Glaucoma. [Updated 2022 Jun 27]. In: StatPearls [Internet]. Treasure Island (FL): StatPearls Publishing; 2024 Jan-. Available: <https://www.ncbi.nlm.nih.gov/books/NBK538217>. 2024;538217.
 28. Pasol J. Neuro-ophthalmic disease and optical coherence tomography: Glaucoma look-alikes. Curr Opin Ophthalmol. 2011; 22(2):124–32.
 29. Greenfield DS. Glaucomatous versus nonglaucomatous optic disc cupping: Clinical differentiation. Semin Ophthalmol. 1999;14(2):95–108.
 30. Kehinde LE, Montes R, Moreno SC. Subconjunctival hemorrhage. Clin Cases Eye Care. 2018;269–71.
 31. Lusthaus J, Goldberg I. Current management of glaucoma. Med J Aust. 2019;210(4):180–7.
 32. Wright C, Tawfik MA, Waisbourd M, Katz LJ. Primary angle-closure glaucoma: an update. Acta Ophthalmol. 2016 May; 94(3):217–25.
 33. Bai HQ, Yao L, Wang DB, Jin R, Wang YX. Causes and treatments of traumatic secondary glaucoma. Eur J Ophthalmol. 2009;19(2):201–6.
 34. Anderson DR. Collaborative normal tension glaucoma study. Curr Opin Ophthalmol. 2003 Apr;14(2):86–90.
 35. Craven ER, Katz LJ, Wells JM, Giamporcaro JE. Cataract surgery with trabecular micro-bypass stent implantation in patients with mild-to-moderate open-angle glaucoma and cataract: Two-year follow-up. J Cataract Refract Surg [Internet]. 2012;38(8):1339–45. Available: <http://dx.doi.org/10.1016/j.jcrs.2012.03.025>

© Copyright (2024): Author(s). The licensee is the journal publisher. This is an Open Access article distributed under the terms of the Creative Commons Attribution License (<http://creativecommons.org/licenses/by/4.0>), which permits unrestricted use, distribution, and reproduction in any medium, provided the original work is properly cited.

Peer-review history:

The peer review history for this paper can be accessed here:
<https://www.sdiarticle5.com/review-history/116423>