



Reconstruction of Bilateral Groin Defects with Mcgregor Flaps: Case Report and Review of Literature

Mohamed Ali Sbai^{1,2}, Amira Gallas^{1,2*}, Mohamed Othmen Chouchène^{1,2},
Houda Belfkih^{1,3} and Riadh Maalla^{1,4}

¹Faculty of Medicine of Tunis, University of Tunis El Manar, Tunisia.

²Department of Burns and Plastic Surgery, Mohamed Taher Al Maamouri Hospital, Nabeul, Tunisia.

³Department of Oncology, Mohamed Taher Al Maamouri Hospital, Nabeul, Tunisia.

⁴Department of Plastic Surgery, Rabta Hospital, Tunis, Tunisia.

Authors' contributions

This work was carried out in collaboration among all authors. All authors read and approved the final manuscript.

Article Information

Editor(s):

(1) Dr. José Francisco de Sales Chagas, São Leopoldo Mandic College, Brazil.

Reviewers:

(1) Capilna Mihai Emil, George Emil Palade University of Medicine, Pharmacy, Science, and Technology, Romania.

(2) Khalid Abdul-Aziz Mowafy, Mansoura University, Egypt.

(3) Bandit Chumworathayi, Khon Kaen University, Thailand.

Complete Peer review History: <http://www.sdiarticle4.com/review-history/63639>

Received 01 November 2020

Accepted 02 January 2021

Published 04 March 2021

Case Study

ABSTRACT

Radiation therapy is an important modality in the treatment of prostate cancer. Its primary goal is eradication of the disease. Several treatment-related sequelae in the primary site of the tumor and the pelvic lymph nodal drainage regions have been reported in the literature. Among these complications, skin radionecrosis lesions of the inguinal region are rarely reported in the literature and reconstruction of the defects resulting from their excision remain challenging for plastic surgeons around the world. Several surgical reconstructive strategies have been described ranging from skin grafts to perforator flaps. Through this paper we aim to highlight the utility and relevance of McGregor flap in its pedicled peninsular form as a local solution for the coverage of loss of soft tissues in the groin region consecutive to skin radionecrosis.

*Corresponding author: E-mail: amiragallas.cpre@gmail.com;

Keywords: Groin region; groin flap; radionecrosis; mcgregor flap.

1. INTRODUCTION

Radiation therapy is an important modality in the treatment of prostate cancer but can cause, as in all other locations, significant harm to healthy surrounding tissue especially the skin, resulting in skin radionecrosis lesions of the inguinal region.

Reconstruction of the groin region can be challenging and several techniques have been used such as skin grafts, fasciocutaneous flaps, musculocutaneous flaps and muscle flaps.

The McGregor flap, also known as “groin flap” or “iliofemoral flap” is an axial flap based on the superficial iliac circumflex artery. It is among the oldest flaps in the history of reconstructive surgery but still find broad indications even with the advent of new pedicled and free flaps. This flap represents an interesting alternative for groin reconstruction and has several advantages.

We present the case of a patient who presented with large skin ulceration bilaterally in the groin region secondary to radiotherapy sessions for lymph node metastases of prostate cancer that was properly covered with two McGregor flaps with a satisfying result.

2. CASE REPORT

A 70-year-old man was operated for a prostate cancer with lymph node metastases for which he had undergone radical prostatectomy completed by conventional external beam radiation therapy at the dose of 70 Gy over 7 weeks with a classic spread of 2 Gy per day and 5 fractions per week, including the primary site of the tumor and the pelvic lymph nodal drainage regions of the prostate, complicated by skin radionecrosis bilaterally in the groin region. He was admitted in our plastic surgery department for persistent loss of soft tissue in the groin region on both sides with painful and difficult-to-heal skin ulceration evolving for a year (Figs. 1a, 1b).

After making sure that there was no recurrence in progress and that the disease was in remission, we performed a superficial excision to sharpen the edges and then opted for two pedicled peninsular McGregor flaps to cover these loss of soft tissues of the groin region.

The preoperative drawing of each flap had the shape of an ellipse which axis was superimposed

on that of the superficial iliac circumflex artery. The harvesting of the flaps started at their distal part without including the aponeurosis of the muscles and stopped at the lateral edge of the sartorius muscle on each side. The pallet was then turned over and applied on the loss of soft tissues, with primary closure of the donor site.

The post-operative care was well conducted and total skin healing was obtained at one month post-operative (Figs. 2a, 2b). The patient was satisfied with the final result as long as he had no longer to do daily local care.

3. DISCUSSION

During radiation therapy of the primary prostate cancer site and the sites of possible regional metastatic disease, such as the seminal vesicle and pelvic lymph nodes, there are many pelvic tissues whose radiation sensitivity may be exceeded including the rectum, proximal anus, rectosigmoid, small intestine, bladder, prostatic urethra and subcutaneous tissues, resulting in numerous treatment-related sequelae such as loss of continence, rectal injury, loss of potency and skin radionecrosis [1]. According to Shipley et al., since the use of megavoltage and multiple treatment beams, reports of fibrosis of subcutaneous tissues are rare [1].

Skin radionecrosis of the groin region may result in defects with or without exposed structures such as femoral vessels and represents a demanding field in reconstructive surgery. Several surgical reconstructive strategies have been described.

Skin grafting can only be employed when granulation tissue is present and the quality of the aesthetic result is often questionable with a high incidence of adherences and consequent contractures [2].

Traditionally, pedicled muscle flaps or myocutaneous flaps are used to provide a safe and well-vascularized coverage of these wounds but are associated with higher morbidity of donor sites compared to groin flap [2,3]. The gracilis, sartorius, rectus femoris (RF), tensor fascia lata, and rectus abdominis muscle flaps are successful workhorses owing to their constant anatomy, ease of harvest, and vicinity to the defect [4-8].

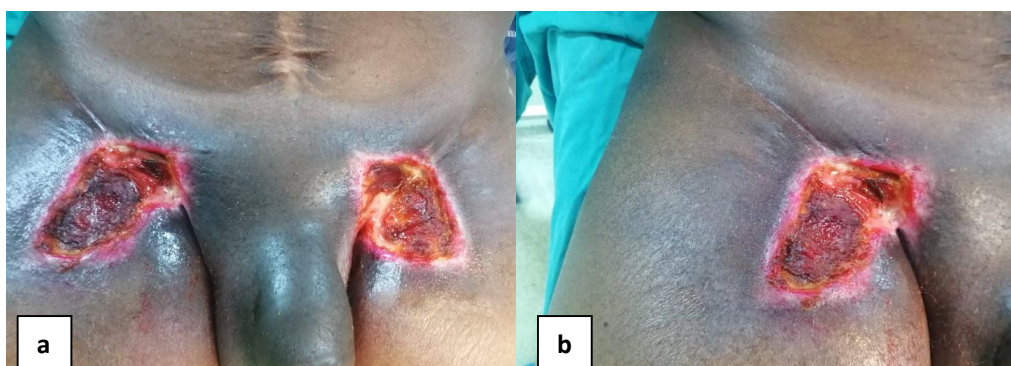

Fig. 1. Skin radionecrosis in bilateral groin regions

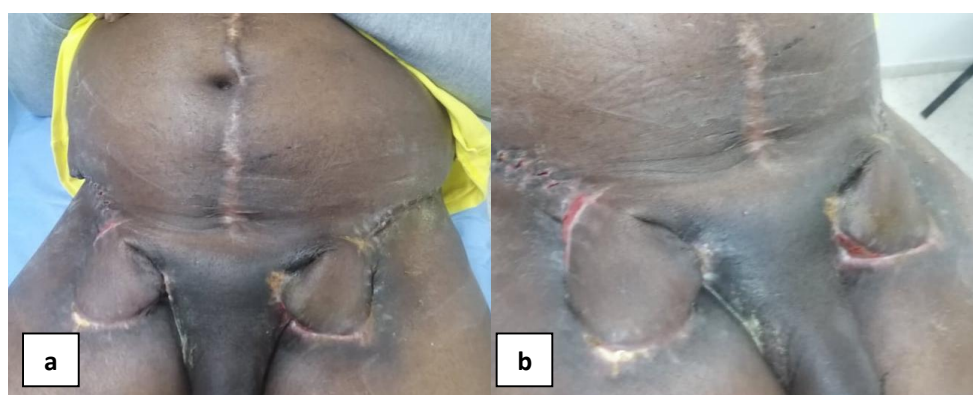


Fig. 2. Result at one month follow up

The Mc Gregor flap is a locoregional pedicled flap that constitutes as well a valid option for groin reconstruction as it has many advantages, in particular the dimensions of the skin palette, the non-sacrifice of a major vascular axis, reliability, with the possibility of a direct closure of the donor area, leaving a hidden scar [9]. Since its first description by Mc Gregor and Jackson in 1972 [10], the groin region has been considered as an almost disposable minimal-morbidity donor site.

An improved version of the Mc Gregor flap is the microsurgically thinned groin flap that provides good color and texture match, excellent thickness match and pliable tissue for coverage of complex defects of the pelvic region, and that was used by Tagliatela Scafati and Lalinde Carrasco for scrotal reconstruction [2].

Benichou et al. proposed to reconstruct the inguinal region using an anterolateral thigh flap based on a proximal vascular pedicle [11].

Recently in 2019, Arvanitakis et al. proposed the use of perforator flaps, consisting in the anterolateral thigh (ALT) flap, the pedicled posteromedial thigh (PMT) perforator flap, and the vertical deep inferior epigastric artery perforator (vDIEP) flap, as a contemporary alternative to established fasciocutaneous and muscle flaps to cover all varieties of groin defects, with minimum donor site morbidity, less post-operative pain, and faster rehabilitation [3].

4. CONCLUSIONS

Even if the main goal of radiation therapy is eradicating the cancer, achieving cure without treatment-related sequelae is such an important goal. Reconstruction of the groin region remains challenging especially when lesions are bilateral. The groin flap is still relevant today and allows solving several problems of coverage of loss of soft tissues in different regions. It is a valid option for groin defect reconstruction and has advantages allowing its use for different types of loss of soft tissue even of large dimensions and

some drawbacks which do not constitute an obstacle to obtaining total patient satisfaction.

CONSENT

It is not applicable.

ETHICAL APPROVAL

It is not applicable.

COMPETING INTERESTS

Authors have declared that no competing interests exist.

REFERENCES

1. Shipley WU, Zietman AL, Hanks GE, Coen JJ, Caplan RJ, Won M, et al. Treatment related sequelae following external beam radiation for prostate cancer: A review with an update in patients with stages T1 And T2 tumor. J Urol. 1994;152(5 Part 2):1799-805.
2. Taglialatela Scafati S, Lalinde Carrasco E. Microsurgically thinned groin flap for partial scrotal reconstruction. J Plast Reconstr Aesthet Surg. 2012;65(5):690-1.
3. Arvanitakis M, Schlagnitweit P, Franchi A, Fritsche E, Chen Y-C, Scaglioni MF. Groin defect reconstruction with perforator flaps: Considerations after a retrospective single-center analysis of 54 consecutive cases. J Plast Reconstr Aesthet Surg. 2019;72(11):1795-804.
4. Daigeler A, Simidjiiska-Belyaeva M, Drücke D, Goertz O, Hirsch T, Soimaru C, Lehnhardt M, Steinau HU. The versatility of the pedicled vertical rectus abdominis myocutaneous flap in oncologic patients. Langenbecks Arch Surg. 2011;396(8):1271-9.
5. Sh C, Vr H, Fc W, Yr C. Short gracilis myocutaneous flaps for vulvoperineal and inguinal reconstruction. Plast Reconstr Surg. 1995;95(2):372-7.
6. Perez-Burkhardt JL, Gonzalez-Fajardo JA, Carpintero LA, Mateo AM. Sartorius myoplasty for the treatment of infected groins with vascular grafts. J Cardiovasc Surg (Torino). 1995;36(6):581-5.
7. Agarwal AK, Gupta S, Bhattacharya N, Guha G, Agarwal A. Tensor fascia lata flap reconstruction in groin malignancy. Singapore Med J. 2009;50(8):781-4.
8. Alkon JD, Smith A, Losee JE, Illig KA, Green RM, Serletti JM. Management of complex groin wounds: preferred use of the rectus femoris muscle flap. Plast Reconstr Surg. 2005;115(3):776-83.
9. Essid L, Sassi S, Khelil K, Sbai MA, Maalla R. The surgical management of a hypogastric dermatofibrosarcoma protuberans. Pan Afr Med J. 2019;34:116.
10. Ian A. McGregor, Ian T. Jackson. The groin flap. Br. J. Plast. Surg. 1972;25:3-16.
11. Benichou L, Caillot A, Vacher C. Groin reconstruction using a pedicled anterolateral thigh flap. J Visc Surg. 2016;153(1):77-80.

© 2021 Sbai et al.; This is an Open Access article distributed under the terms of the Creative Commons Attribution License (<http://creativecommons.org/licenses/by/4.0>), which permits unrestricted use, distribution, and reproduction in any medium, provided the original work is properly cited.

Peer-review history:
The peer review history for this paper can be accessed here:
<http://www.sdiarticle4.com/review-history/63639>