

Ischemic Retinal Vasculitis after Previous Toxoplasma Chorioretinitis

Vesela Mitkova-Hristova , Nina Stoyanova 

Department of Ophthalmology, Faculty of Medicine, Medical University-Plovdiv, Plovdiv, Bulgaria

Email: vesela_mitkova@abv.bg

How to cite this paper: Mitkova-Hristova, V. and Stoyanova, N. (2022) Ischemic Retinal Vasculitis after Previous Toxoplasma Chorioretinitis. *Open Journal of Ophthalmology*; 12, 397-406.

<https://doi.org/10.4236/ojoph.2022.124037>

Received: August 16, 2022

Accepted: November 6, 2022

Published: November 9, 2022

Copyright © 2022 by author(s) and Scientific Research Publishing Inc.

This work is licensed under the Creative Commons Attribution International License (CC BY 4.0).

<http://creativecommons.org/licenses/by/4.0/>



Open Access

Abstract

Introduction: Ischemic retinal vasculitis is an inflammatory disease affecting the retinal vessels. Visual acuity decreases due to macular ischemia, macular edema, neovascularization leading to vitreous hemorrhage, fibrovascular proliferation or tractional retinal detachment. **Purpose:** To present the case of a patient with ischemic retinal vasculitis. **Material and Methods:** The case involves a 34-year-old woman. The following tests were performed: complete blood count, biochemistry, coagulogram, rheumatological tests, serum calcium level, angiotensin-converting enzyme, CT of the lungs, MRI of the brain and spine, serological tests for: cytomegalovirus, herpes simplex virus (type 1 and 2), varicella-zoster virus, toxoplasmosis, tuberculosis, syphilis, as well as fluorescein angiography and optical coherence tomography. **Results and Discussion:** The patient was admitted to the hospital with visual acuity of the right eye, 0.8/0.9, and of the left eye, 1.0. The intraocular pressure in both eyes was normal: 14 mmHg in the right eye and 15 mmHg in the left eye. The following pathological finding was detected in the right eye fundus: an old chorioretinal cicatrix under the inferior temporal vascular arch with an ischemic exudate next to it, occlusion of the inferior temporal retinal arterial and venous branches, neovascularization and a preretinal hemorrhage. Fluorescein angiography showed delayed filling of the affected vessels, neovascularization, and major ischemia in the lower temporal part of the retina. The results of the serological tests for varicella zoster virus, herpes simplex virus type 1 and toxoplasmosis were outside the reference ranges. The patient was treated with Clindamycin and Acyclovir. Emergency laser therapy was performed in the ischemic retina area. Previous toxoplasma chorioretinitis was diagnosed, which had led to ischemic retinal vasculitis with sectoral involvement of the retinal vessels. The patient has been monitored over 3 - 4 month periods, showing high visual acuity and stable ocular condition. **Conclusion:** Patients with ischemic retinal vasculitis are a challenge when it comes to cla-

rifying the etiological diagnosis. Treatment on time prevents severe and irreversible loss of vision. Occlusive vasculitis is a rare complication of ocular toxoplasmosis, but must be taken into consideration when young patients are involved.

Keywords

Retinal Occlusion, Uveitis, Ocular Toxoplasmosis

1. Introduction

Toxoplasmosis is a leading cause of infectious posterior uveitis. The most common ocular clinical manifestation of the disease is unilateral chorioretinitis with vitritis [1] [2] [3]. Eyes are affected by an inflammatory process more frequently in acquired, postnatal infection. The factors determining the severity of the disease on the part of the host are: age, immune status, cultural and hygienic habits, race and geographical location. As to the causative agent, *Toxoplasma gondii*, the genotype, stage of development and amount of the parasite at the time of inoculation are important [4]. Toxoplasma chorioretinitis usually follows a self-limiting course, but may lead to irreversible visual loss if the macula and optic nerve are involved in the inflammatory process [5].

The most common complications of toxoplasma chorioretinitis are: cystoid macular edema and vasculitis, less often occlusion of arterioles or venules [6]. The involvement of retinal vessels in the disease results from the production and deposition of antigen-antibody complexes in the vessel walls, as well as sectoral mononuclear cell infiltration. Venous occlusions are more common than arterial retinal occlusions [1] [7] [8]. The main risk factor for vaso-occlusion is retinal ischemia, which stimulates the development of neovascularization. Neovascularization is a rare and late complication, which may lead to vitreous hemorrhage, fibrovascular proliferation or tractional retinal detachment [9].

The purpose of this article is to present an interesting clinical case of a patient with ischemic retinal vasculitis, as well as our approach when establishing a clinical diagnosis.

2. Clinical Case

The clinical case presented is of a 34-year-old woman, an infectious disease doctor, who was admitted to the University Eye Clinic, the town of Plovdiv, Bulgaria, in November 2019 with complaints of slightly reduced vision and a right eye floater.

Informed consent was obtained from the patient for the presentation and publication of her disease data.

The patient's complaints date back to three and a half years ago (May 2016), when she experienced reduced visual acuity and spontaneous pain in the affected right eye. The presented medical documentation concerning the right eye de-

scribed fine precipitates on the endothelium of the cornea, and in the fundus, a cotton-wool exudate under the inferior temporal vascular branch, as well as vessels with tortuosity. The patient was diagnosed with optic neuritis of the right eye and received local non-specific anti-inflammatory therapy. A few months later (August 2016), the central visual acuity of the right eye, involved in the process, was restored but fluorescein angiography revealed occlusion of the lower temporal branch of arteria centralis retinae, so active monitoring was recommended to the patient.

In October 2019, the patient was hospitalized in the neurological department with complaints of severe dizziness, unstable gait, headache and staggering.

In November 2019 she was admitted to our hospital with visual acuity of the right eye, 0.8/0.9, and of the left eye, 1.0. The intraocular pressure was normal, respectively: 14 mmHg of the right eye and 15 mmHg of the left eye, according to Goldmann tonometry. The anterior segment of both eyes was normal too. The following finding was visualized in the fundus of the right eye: chorioretinal cicatrix, located below the inferior temporal arch and an ischemic exudate located right next to it, as well as neovascularizations, preretinal hemorrhage and occlusion of the inferior temporal artery with concomitant ischemia in the inferior and temporal peripheral retina (**Figure 1**). The ophthalmoscopic finding in the left eye showed no pathology.

In order to clarify the finding, fluorescein angiography (FA), optical coherence tomography (OCT) and perimetry were performed. During the FA of the right eye, delayed filling of the inferior temporal arterial and venous vessels was visualized, and in the final angiographic phases, leakage from neovascularizations and major ischemia from a missing capillary perfusion in the inferior and temporal peripheral retina was established (**Figure 2**). The FA detected a normal finding in the left eye. The OCT revealed slight thickening of the retina in the para- and perifoveolar inferior zone (**Figure 3**) in the right eye and a normal OCT macular finding in the left eye. The perimetry visualized a defect involving mainly the upper nasal part of the visual field, corresponding to the clinical finding in the right eye (**Figure 4**) and a normal perimeter in the left eye.

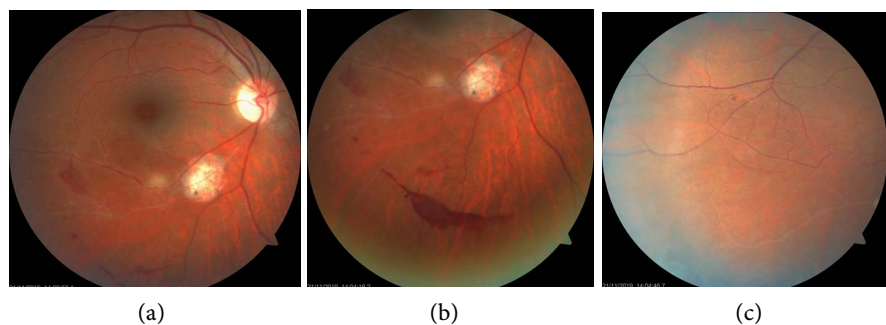


Figure 1. Ocular fundus of the right eye: (a) chorioretinal cicatrix, located below the inferior temporal arch and an ischemic exudate located right next to it; (b) preretinal hemorrhage and neovascularizations; (c) occlusion of the inferior temporal artery with concomitant ischemia in the inferior and temporal peripheral retina.

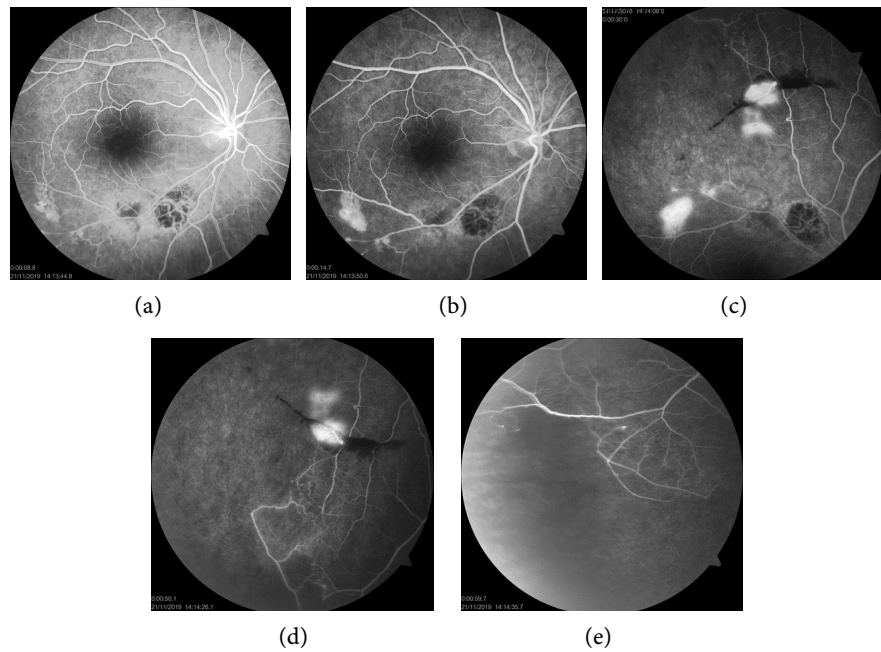


Figure 2. FA of the right eye: (a) and (b) arteriovenous phases show delayed filling of the inferior-temporal arterial and venous vessels; (c) and (d) late angiographic phases show leakage from neovascularizations; (c), (d) and (e) major ischemia from a missing capillary perfusion in the temporal and the inferior peripheral retina.

The ophthalmological examination and tests which we performed revealed a combined involvement of the vessels, arterioles and venules. The following diagnostic approach was applied: complete blood count, differential blood count, urine, creatinine, urea, ESR, C-reactive protein, rheumatoid factor, ANA, c-ANCA, p-ANCA, coagulogram, Antiphospholipid syndrome test, serum Ca^{2+} level, angiotensin-converting enzyme, HLA-B51 typing, T-Spot.TB, serological tests for: toxoplasmosis, lues, herpes simplex (HSV) (types 1 and 2), varicella zoster virus (VZV) and cytomegalovirus (c 1). Computer axial tomography of the lungs, magnetic resonance imaging of the central and spinal cord were performed and no pathological changes were found. Consultations with a neurologist, rheumatologist and an infectious disease specialist were made and no concomitant diseases were found.

The laboratory tests showed slightly elevated immunoglobulins M (Ig M-1.4 IU/ml), as well as immunoglobulins G (IgG-3.97 IU/ml) for HSV type 1, slightly elevated IgG (1.5 IU/ml) for toxoplasmosis and significantly higher IgG (1730 IU/l) values for VZV (Table 1).

Due to the high VZV IgG titers, we started Acyclovir therapy in moderate doses, as there was no evidence of active inflammation (a starting dose of 5×400 mg for 10 days, with subsequent dose reduction over a period of 3 months), and performed emergency laser therapy (Figure 5).

During a follow-up examination, the patient produced old documentation from 2016 for the first time, which revealed slightly elevated IgM (1.5 IU/ml) and significantly elevated IgG (650 IU/ml) for toxoplasmosis. She explained that

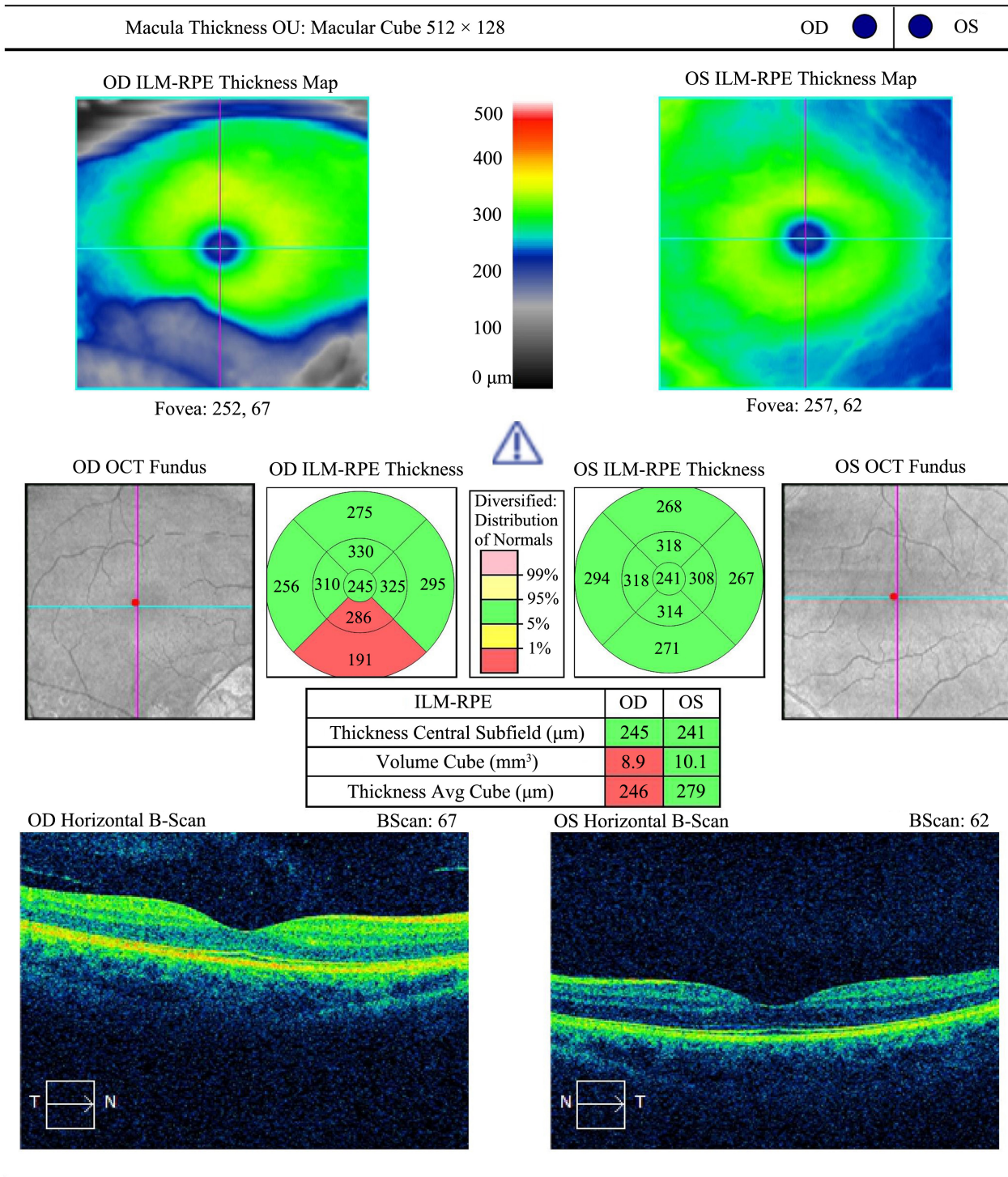


Figure 3. OCT in the right eye shows slight thickening of the retina in the para- and perifoveolar inferior zone and a normal macular finding in the left eye.

at the beginning of the disease she had been treated with Clindamycin; there were some suspicions of toxoplasma chorioretinitis; but after consultation with a parasitologist, the etiological diagnosis was rejected, due to which this information was ignored.

Table 1. The results of the laboratory investigations.

Laboratory investigation	Result
Complete blood count	RBC 4.66 10 ¹² /l; HGB 153 g/l; HCT 0.412 l/l; MCV 88.6 fl; MCH 32.8 pg; MCHC 371 g/l; RDW-CV 14.1%; RDV-SD 45 f/l; PLT 241 10 ⁹ /l; MPV 8.7 fl; WBC 10.7 g/l
Differential blood count	Lym 2.4 g/l; Neo 7.5 g/l; Eos 0.2 g/l; Mono 0.8 g/l; Baso 0.07 g/l
Urine	pH 5.0; Protein (-) negative; Glucose (-) negative; Ketones (-) negative; Billirubin (-) negative; Specific gravity 1015.
Creatinine	77 mmol/l
Urea	3.9 mmol/l
ESR	5 mm/h
C-reactive protein	5.0 mg/l (negative)
Rheumatoid factor	<2.0 (negative)
Calcium ionized	1.146 mmol/l
Angiotensin-converting enzyme	23.1 U/l
Koagulation	INR 0.93; aPTT 26.7 sec; Fibrinogen 2.94 g/l; Prothrombin time test 11.1 sec
Antiphospholipid syndrome test	Negative
ANA	Negative
c-ANCA	Negative
p-ANCA	Negative
HLA-B51 typing	Negative
T-Spot.TB	Negative
Toxoplasmosis	Anti-TOXO IgM (0.15); IgG (1.5 IU/ml)
Lues	Negative
Herpes simplex types 1	IgM 1.4 IU/ml; IgG 3.97 IU/ml
Herpes simplex type 2	IgM 0.4 IU/ml; IgG 0.6 IU/ml
Varicella zoster virus	IgM 0.26; IgG 1730 IU/l
Cytomegalovirus	IgM (-) negative; IgG (-) negative

Upon being provided with this new medical documentation, we were able to establish a diagnosis of occlusive retinal vasculitis as a result of previous toxoplasma chorioretinitis.

The patient has been monitored over 3 - 4 month periods, showing high visual acuity of the right eye, 0.9/1.0 and stable ocular condition.

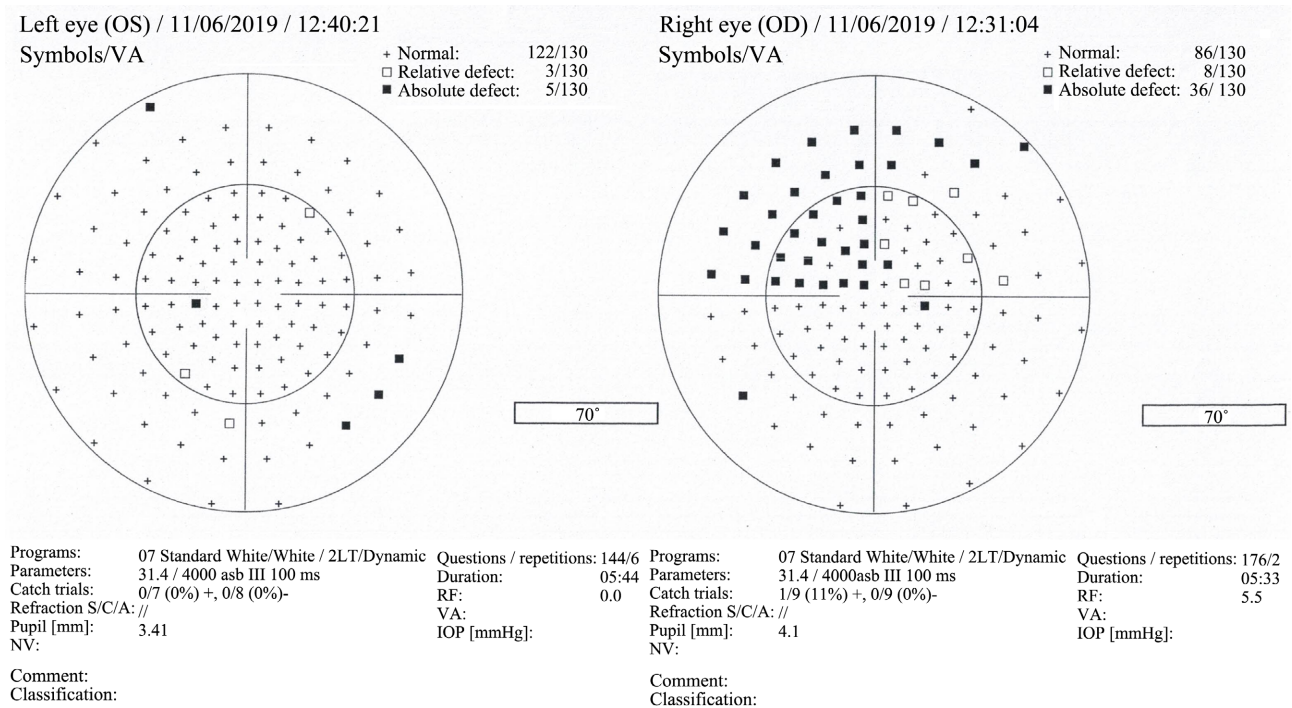


Figure 4. Perimetry in the right eye shows a defect involving mainly the upper nasal part of the visual field (on the left side) and a normal find in the left eye (on the right side).

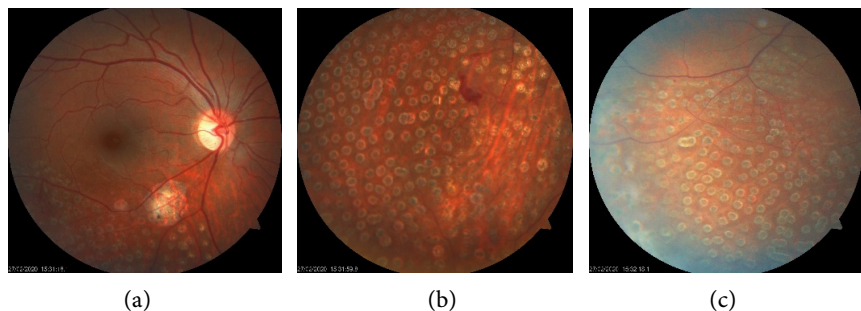


Figure 5. Laser therapy of the right eye of the involved inferior and temporal ischemic peripheral retina.

3. Discussion

Ocular toxoplasmosis is most frequently observed in individuals at the age of 20 - 40 years [10], in our case the patient being 31 at the onset of the disease. The pathogenesis of the disease has not been studied well. *Toxoplasma gondii* can reach the retina through the retinal or choroidal vascular network. Histopathological and clinical studies reveal that tachyzoites enter the human eye most often through retinal vessels [4]. As a result, the inflammatory process begins in the superficial layers of the retina, after which it progresses and may affect the entire retina, as well as the adjacent structures, *i.e.* the choroid and vitreous [11].

With ocular toxoplasmosis, retinal vasculitis most frequently affects the adjacent venous vessels, which fall into the area of active chorioretinitis. Arterioles are less commonly involved in the inflammatory process, or vessels away from

the primary lesion [10]. In the clinical case subject to this discussion, the damaged vessels are located in the area of the chorioretinal cicatrix. The location of the active chorioretinal focus is supposed to exert direct compression onto the arterioles, causing interruption of blood flow. Another possible mechanism leading to arterial occlusion is the occurrence of vascular spasm near the inflammation. In the absence of an active chorioretinal focus, the inflammatory infiltration and thickening of the vascular wall are the factors which cause interruption of the blood flow. Spasm of the arterioles near the chorioretinal focus, in combination with increased blood viscosity and suppression of coagulation due to the release of free heparin from mast cells, leads to thrombosis [12]. In fact, histological results indicate that when it comes to uveitis, what is observed is perivasculitis from perivascular infiltration of lymphocytes rather than true vasculitis of the vascular walls [13].

In the clinical case subject to this discussion, the affected retinal vessels pass through the chorioretinal cicatrix without any criss-crossing, although combined arteriovenous occlusion is most frequently observed in the area of chorioretinal lesion at the spot of vessel criss-crossing, probably due to their common adventitia in these areas. Aggio *et al.* described a similar case of combined vascular retinal (arterial and venous) occlusion, affecting the inferior temporal arch in a similar way, in a 22-year-old patient. Three months later, during control FA, they did not detect any areas of hypoperfusion [11]. This period is shorter compared to the one described in our case, where there was evidence of ischemia and neovascularization more than 3 years after the onset of the disease. We are of the opinion that such patients must be continuously monitored after the illness.

In several studies published in literature, the authors describe choroidal neovascularization in the area of the chorioretinal cicatrix [6] [14] [15]. It is thought to be the result of retinal vessel endothelial cells being preferred by the toxoplasma tachyzoite. Tachyzoites can reach the endothelial cells of retinal vessels by infecting blood leukocytes, using them as carriers. Another possible mechanism is their circulation in the blood as free parasites and direct infection of endothelial cells [16]. Once in the retina, tachyzoites can migrate through all of its layers, reaching the pigment epithelium. The infected pigment epithelial cells initiate activin receptor-like kinase 4 and subsequently factor-1, activated by hypoxia, which is a key transcription factor for vascular endothelial growth factor [17]. Apart from this pathogenetic mechanism, another reason is the obstruction of venous flow during the acute phase of active inflammation, as well as ruptures in Bruch's membrane and choriocapillaris, thus stimulating vasoproliferation [15].

The diagnosis of retinal vasculitis is established with the help of FA. The presence of neovascularizations, as in the case described by us, are a sign of late secondary complications, requiring immediate laser therapy in order to prevent recurrent hemophthalmos, tractional retinal detachment and/or neovascular glaucoma. The differential diagnosis of vasculitis, which mainly affects the venous vessels of the retina, comprises: Behcet's disease, tuberculosis, sarcoidosis,

multiple sclerosis and pars planitis, while arterioles are more often involved in the inflammatory process during acute retinal necrosis, idiopathic retinal vasculitis, aneurysms and neuroretinitis, systemic lupus erythematosus, CMV retinitis. A distinctive feature of ocular toxoplasmosis is focal necrotizing retinitis, which leads to an atrophic scar with hyperpigmentation along the borders [9]. When diagnosing our patient, we took into consideration the location of the lesion in the posterior eye pole and the self-limiting course of the disease. Although the laboratory results showed elevated serum levels of VZV antibodies, the patient's young age, as well as the lack of former zoster dermatitis or shingles ophthalmicus, indicated previous toxoplasma chorioretinitis, which had caused ischemic vasculitis with sectoral involvement of retinal arteries and veins. It is likely that the high varicella zoster antigen titers are the result of a strained immune system. The patient works as a doctor in an infectious disease department and has frequent contact with the causative agent.

4. Conclusion

Patients with ischemic retinal vasculitis are a challenge when it comes to clarifying the etiological diagnosis. Timely treatment prevents severe and irreversible visual loss. Occlusive vasculitis is rarely observed in ocular toxoplasmosis, but must be subject to discussion when young patients are involved. Follow-up monitoring after the illness must be continuous, as neovascularization is a late complication.

Conflicts of Interest

The authors declare no conflicts of interest regarding the publication of this paper.

References

- [1] Arai, H., Sakai, T., Okano, K., *et al.* (2014) Presumed Toxoplasmic Central Retinal Artery Occlusion and Multifocal Retinitis with Perivascular Sheathing. *Clinical Ophthalmology*, **8**, 789-792. <https://doi.org/10.2147/OPTH.S58669>
- [2] Smith, J.R. and Cunningham Jr., E.T. (2002) A Typical Presentations of Ocular Toxoplasmosis. *Current Opinion in Ophthalmology*, **13**, 387-392. <https://doi.org/10.1097/00055735-200212000-00008>
- [3] Crosson, J., Kuthyar, S., Shantha, J., *et al.* (2020) Toxoplasmosis Chorioretinitis Mimicking Acute Retinal Necrosis Associated with Local Corticosteroid. *International Journal of Retina and Vitreous*, **6**, Article No. 21. <https://doi.org/10.1186/s40942-020-00225-0>
- [4] Kalogeropoulos, D., Sakkas, H., Mohammed, B., *et al.* (2022) Ocular Toxoplasmosis: A Review of the Current Diagnostic and Therapeutic Approaches. *International Ophthalmology*, **42**, 295-321. <https://doi.org/10.1007/s10792-021-01994-9>
- [5] Орйfice, F., Vasconcelos-Santos, D.V., Cordeiro, C.A., *et al.* (2013) Toxoplasmosis. In: Foster, C.S. and Vitale, A.T., Eds., *Diagnosis and Treatment of Uveitis*, Jaypee-Highlights, New Delhi, 543-568. https://doi.org/10.5005/jp/books/11822_35
- [6] Kabedi, N. and Mwanza, J. (2021) Neuroretinitis and Juxtapapillary Retinochoroidi-

- tis as Atypical Presentations of Ocular Toxoplasmosis. *International Medical Case Reports Journal*, **14**, 657-661. <https://doi.org/10.2147/IMCRI.S332147>
- [7] Williamson, T.H. and Meyer, P.A. (1991) Branch Retinal Artery Occlusion in Toxoplasma Retinochoroiditis. *British Journal of Ophthalmology*, **75**, Article No. 253. <https://doi.org/10.1136/bjo.75.4.253-a>
- [8] Chiang, E., Goldstein, D.A., Shapiro, M.J. and Mets, M.B. (2012) Branch Retinal Artery Occlusion Caused by Toxoplasmosis in an Adolescent. *Case Reports in Ophthalmology*, **3**, 333-338. <https://doi.org/10.1159/000343262>
- [9] Abu El-Asrar, A., Herbot, C. and Tabbara, K. (2009) Differential Diagnosis of Retinal Vasculitis. *Middle East African Journal of Ophthalmology*, **16**, 202-218.
- [10] Butler, N.J., Furtado, J.M., Winthrop, K.L. and Smith, J.R. (2013) Ocular Toxoplasmosis II: Clinical Features, Pathology and Management. *Clinical & Experimental Ophthalmology*, **41**, 95-108. <https://doi.org/10.1111/j.1442-9071.2012.02838.x>
- [11] Aggio, F., Novelli, F., Rosa, E. and Nobrega, M. (2016) Combined Branch Retinal Vein and Artery Occlusion in Toxoplasmosis. *Arquivos Brasileiros de Oftalmologia*, **79**, 189-191. <https://doi.org/10.5935/0004-2749.20160054>
- [12] Kahloun, R., Mbarek, S., Khairallah-Ksaa, I., *et al.* (2013) Branch Retinal Artery Occlusion Associated with Posterior Uveitis. *Journal of Ophthalmic Inflammation and Infection*, **3**, 16-20. <https://doi.org/10.1186/1869-5760-3-16>
- [13] Talat, L., Lightman, S. and Tomkins-Netzer, O. (2013) Ischemic Retinal Vasculitis and Its Management. *Journal of Ophthalmic Inflammation and Infection*, **3**, 16-29.
- [14] Hegde, S., Relhan, N., Pathengay, A., *et al.* (2015) Coexisting Choroidal Neovascularization and Active Retinochoroiditis—An Uncommon Presentation of Ocular Toxoplasmosis. *Journal of Ophthalmic Inflammation and Infection*, **5**, 22. <https://doi.org/10.1186/s12348-015-0051-2>
- [15] Khandwala, N.S., Hyde, R.A. and Besirli, C.G. (2021) Toxoplasma Retinochoroiditis with Chorioretinal Neovascularization in a Young Patient. *Case Reports in Ophthalmology*, **12**, 259-263. <https://doi.org/10.1159/000512286>
- [16] Smith, J., Ashander, L., Arruda, S., *et al.* (2021) Pathogenesis of Ocular Toxoplasmosis. *Progress in Retinal and Eye Research*, **81**, Article ID: 100882. <https://doi.org/10.1016/j.preteyeres.2020.100882>
- [17] Lis, A., Wiley, M., Vaughan, J., *et al.* (2019) The Activin Receptor, Activin-Like Kinase 4, Mediates *Toxoplasma gondii* Activation of Hypoxia Inducible Factor-1. *Frontiers in Cellular and Infection Microbiology*, **9**, Article No. 36. <https://doi.org/10.3389/fcimb.2019.00036>