



## The Effect of Aqueous Extract of Vernonia Amygdalina (Bitter Leaf) on Antioxidants and the Liver of Rabbits on High Cholesterol Diet

O. Abdulmalik<sup>1\*</sup> and O. O. Oladapo<sup>1</sup>

<sup>1</sup>Department of Anatomy, Faculty of Basic Medical Sciences, College of Medicine, University of Ibadan, Nigeria.

### Authors' contributions

This study was carried out in collaboration between both authors. Author OA designed the study, author OOO supervised the experiment. Both authors wrote the protocol, managed the literature searches and prepared the manuscript. Both authors read and approved the final manuscript.

### Article Information

DOI: 10.9734/IJBCRR/2020/v29i930228

#### Editor(s):

- (1) Dr. K. V. Ramanath, Dayanand Sagar University, India.
- (2) Prof. Cheorl-Ho Kim, Sungkyunkwan University, South Korea.

#### Reviewers:

- (1) José G. Parra, Universidad of Carabobo, Venezuela.
- (2) Jaya Vejayan, Universiti Malaysia Pahang, Malaysia.

Complete Peer review History: <http://www.sdiarticle4.com/review-history/63158>

Original Research Article

Received 18 September 2020  
Accepted 24 November 2020  
Published 28 November 2020

### ABSTRACT

**Aims:** To determine the effect of *V. amygdalina* on the levels of antioxidants and the liver of rabbits fed on a atherogenic diet.

**Study Design:** Prospective experimental study.

**Place and Duration of study:** Study lasted 14 weeks at Department of Anatomy, University of Ibadan, Nigeria.

**Methodology:** Eighteen male rabbits were randomly divided into three groups comprising control, high cholesterol diet and high cholesterol diet plus 200mg/kg of aqueous extract of *V. amygdalina*. The animals were fed a normal animal chow, or a diet supplemented by 0.5% cholesterol and 1% methionine for twelve weeks. Subsequently, serum was obtained for liver function tests. Samples of the liver of the animals were obtained for antioxidant tests and histology.

**Results:** Aspartate transaminase was significantly elevated in atherogenic diet only group compared to animals on normal diet. There was also no statistically significant difference across the three groups in the alanine transaminase values. Superoxide dismutase were significantly reduced

\*Corresponding author: E-mail: omotolawhite@yahoo.com;

in animals that were administered extract. Malondialdehyde was not statistically different across the three groups.

The histology of the liver of the animals on high cholesterol diet (with and without extract administration) revealed similar microscopic presence of fatty infiltration of the liver.

**Conclusion:** The use of high cholesterol diet for a duration of twelve weeks in rabbits resulted in significant increased relative liver weight, aspartate transaminase, superoxide dismutase and hepatic microvesicular steatosis. Furthermore, the use of 200mg/kg of aqueous extract of *V. amygdalina* had ameliorative effect on the level of superoxide dismutase. It did not have a measurable effect on the malondialdehyde, liver enzymes and liver histology.

**Keywords:** *V. amygdalina*; high lipid diet; high cholesterol diet; antioxidants; rabbits; liver function tests.

## 1. INTRODUCTION

The liver is very important in lipid metabolism. Lipogenesis within the body and dietary fats leads to hepatic accumulation of lipids [1]. A high cholesterol diet increases free fatty acid in the liver. This is esterified to glycerol to form triglycerides which subsequently accumulates within the hepatocytes. Hepatic damage may ensue [2] and is accompanied by increased serum levels of liver enzymes alanine transaminase and aspartate transaminase [3]. Some researchers [4,5,6] have demonstrated that excessive dietary cholesterol results in early lesions of non-alcoholic fatty liver disease (NAFLD).

The accumulation of triglycerides in hepatocytes also makes the cell vulnerable to secondary injury [7]. This secondary insult ensues from oxidative stress which is present in hyperlipidaemic state. Histological characteristics of NAFLD includes lipid vesicles in hepatocytes, ballooning and degeneration of hepatocytes, inflammatory infiltrates, fibrosis and cell death [8] with distortion of lobular architecture. Ballooning injury consist of enlarged hepatocytes that have irregularly clumped cytoplasm [9].

While orthodox medicine is generally accepted and preferred globally, the use of herbs and traditional medicine is an acceptable alternative in many regions of the world. Traditional medicine is commonly used in the developing countries due to either lack of financial resources or lack of access to orthodox medicine [10]. *Vernonia amygdalina* is a vegetable that is commonly cultivated and consumed in various parts of Africa. Traditional medical practitioners, herbalists, and local healers in West Africa recommend the consumption of water infused *V. amygdalina* for their clients. The roots and the leaves of this plant are used to treat fever [11,

12], as antimicrobial [13] and for gastrointestinal disorders [14]. The stem and root are used as chewing sticks in many West Africa countries such as Cameroon, Ghana, and Nigeria.

It has also been found to be beneficial in its effect on antioxidants in studies in rats [15,16]. This study was designed to investigate if the concomitant administration of *V. amygdalina* with high cholesterol diet will reduce the hepatotoxic effect of the diet.

## 2. MATERIALS AND METHODS

A randomized longitudinal experimental study design was utilized.

### 2.1 Experimental Animals

Eighteen male rabbits weighing  $1000 \pm 200$  grams and aged 2-3months were used for the study. They were adapted to laboratory handling for one week and then randomly divided into three equal groups as follows:

Control group fed on normal chow containing 9.3% moisture, 18.7% crude protein, 3.6% crude fat, 7.8% fiber, 11.9% crude ash, 0.3% salt and 0.3% vitamin mixture for 12 weeks;

Cholesterol group fed on high cholesterol diet comprising of normal chow supplemented with 0.5% cholesterol, 1% methionine and 5% groundnut oil (w/w) for 12 weeks. This diet has been demonstrated to produce hyperlipidemia in rabbit by previous studies [17,18];

Cholesterol and extract group fed on high cholesterol diet as described above and 200 mg/kg of aqueous extract of *V. amygdalina* daily for 12 weeks.

The composition by weight of the normal diet and the high cholesterol diet used in this study is represented in Table 1.

## 2.2 Study Procedure

The animals were housed in individual cages and fed chow at 5% of body weight daily and had free access to water. Cholesterol powder was procured from AMRESCO Ohio USA.

## 2.3 Preparation of Extract

*V. amygdalina* leaves were harvested during the rainy season in Iwo town, South Western Nigeria. It was authenticated at the Botany department of the University of Ibadan (with reference number UIH-22432).

The leaves were rinsed with water to remove extraneous materials. They were subsequently spread to dry indoors until a constant dry weight was obtained. It was ground into powder. At the end of milling, 2.4 kg of ground leaves was obtained. The ground leaves were soaked in distilled water for 24 hours with stirring of the mixture. The mixture was subsequently filtered through a muslin bag and subsequently with Whatmann filter paper. Concentration of the extract was done using a rotary evaporator at 45°C. The extract was dried in a vacuum oven at 45°C and pressure of 600 mmHg. The resultant yield was 122 g of extract giving a percentage yield of 5.08%. 4 g of the extract was used for qualitative phytochemical analysis. The remaining extract was stored in a glass jar in a refrigerator. This extraction technique has been previously described [15].

## 2.4 Administration of Extract

A gavage needle was used to deliver the extract to animals in the cholesterol and extract group, at a dose of 200 mg/kg once daily for 12 weeks. It was reconstituted with distilled water for ease of administration, on a daily basis as required.

## 2.5 Sample Collection

At the end of the study, serum was obtained from the animals to analyse alanine transaminase (ALT) and aspartate transaminase (AST). This analysis was done with a Landwind auto-chemistry analyser. The animals were euthanized, and the livers of the animals were

removed and weighed. Liver samples were processed for light microscopy using haematoxylin and eosin staining technique. Furthermore, phosphate buffered homogenized liver samples were analysed for antioxidants: superoxide dismutase (SOD) and malondialdehyde (MDA). For the determination of MDA, total amount of lipid peroxidation products present in the liver samples was estimated by the thiobarbituric acid method as previously described [19]. To measure SOD, its ability to inhibit the auto-oxidation of epinephrine at pH of 10.2 was used as a basis for assay [20].

## 2.6 Data Analysis

Results are expressed as mean  $\pm$  standard deviation (SD). Comparison across the groups of all parameters was done using analysis of variance (ANOVA) test followed by Tukey's post-hoc analysis performed on SOD, AST and relative liver weight parameters where ANOVA showed statistically significant differences ( $P < 0.05$ ). The level of statistical significance was set at 95% with  $P < 0.05$ . Statistical analyses were computed using R studio version 1.2.5042

## 3. RESULTS

Summary statistics was obtained from each experimental group and analysis of variance (ANOVA) was used to compare the results from the biochemical tests conducted. The relative liver weight was significantly increased in the two groups of animals that were fed a high cholesterol diet compared to the animals on normal diet. The level of ALT was not statistically different in the three groups. AST was significantly elevated in animals with high cholesterol diet. In addition, the level of superoxide dismutase was significantly reduced in the animals that had extract administration. This is presented in Table 2.

The following box and whisker plots illustrate the distribution in the three experimental groups of SOD, MDA, ALT enzyme and AST enzyme in Figs. 1, 2, 3 and 4 display respectively.

Light microscopy of the hematoxylin and Eosin staining of the liver showed increase in the size of the hepatocytes with ballooning of the cells. It also revealed microvesicular features in the hepatocytes. The photomicrographs are presented in Fig. 5.

**Table 1. Composition of experimental diet**

Normal chow	Percentage	High cholesterol diet	Percentage
Crude protein	18.7	Normal chow	93.5
Crude fat	3.6	Cholesterol powder	0.5
Carbohydrate	59.6	Methionine powder	1.0
Crude fiber	7.8	Groundnut oil	5.0
Ash	10.3		

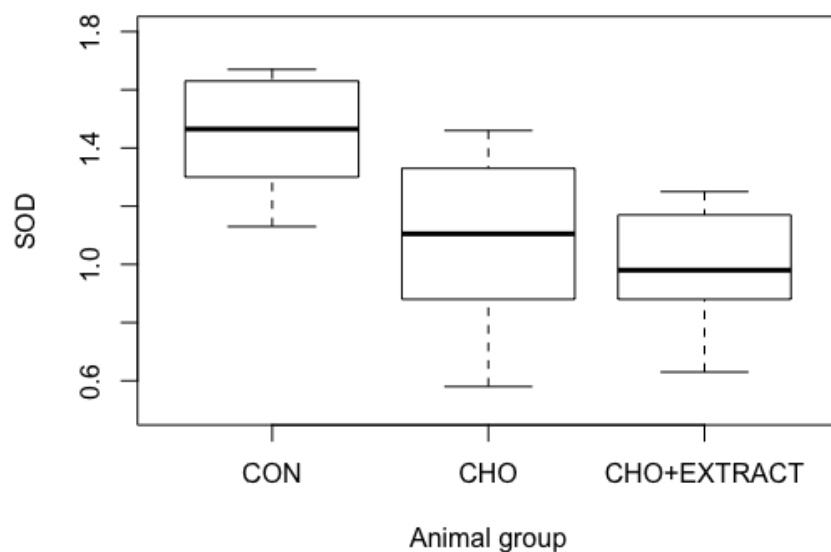
**Table 2. Comparison of the biochemical analysis in the experimental groups of rabbits**

	CON Mean (SD)	CHO Mean (SD)	CHO+EXTRACT Mean (SD)	P value
Superoxide Dismutase (SOD) unit/mg	1.44 (0.22)	1.08 (0.32)	0.98 (0.22)	0.02*
Malonaldehyde (MDA) μmol/mg	0.83 (0.10)	0.73 (0.13)	0.68 (0.06)	0.08
Alanine aminotransferase (ALT) IU/L	22.32 (10.3)	20.13 (10.38)	13.85 (7.43)	0.30
Aspartate aminotransferase (AST) IU/L	14.30 (2.19)	23.42 (5.58)	18.67 (3.43)	0.005*
Relative liver weight (g/100g body weight)	2.78(0.39)	3.99(0.20)	3.64(0.40)	<0.001*

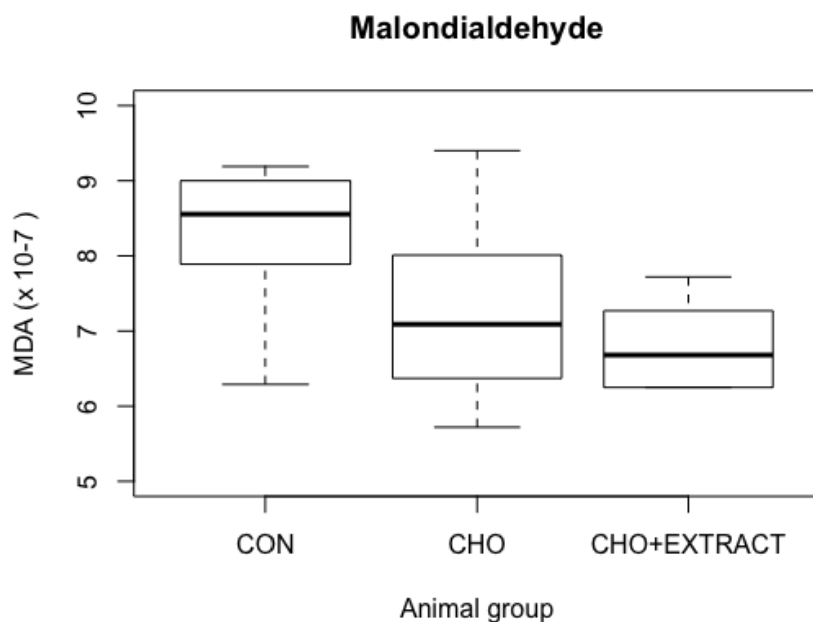
\*  $P < 0.05$

CON: normal chow, CHO: high lipid diet, CHO+EXTRACT: high lipid diet + 200mg/kg/day of aqueous extract of *V. amygdalina*

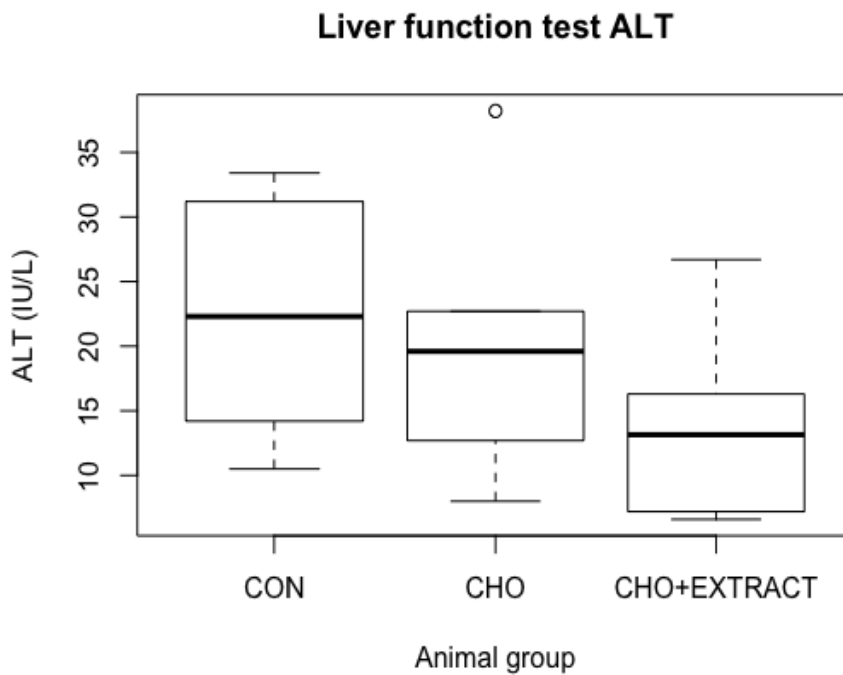
### Superoxide dismutase



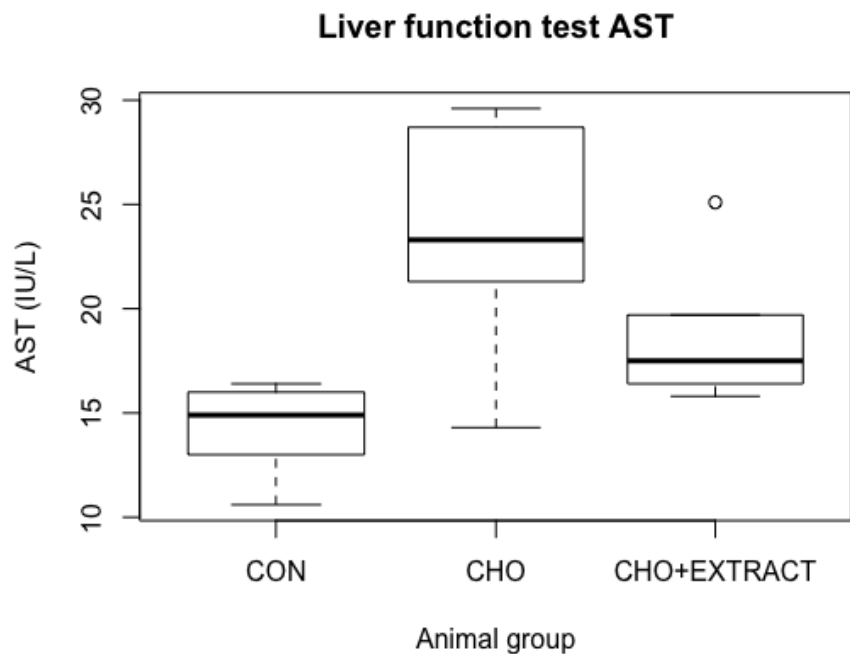
**Fig. 1. Box and whisker plot showing the summary of the SOD (unit/mg) of the animals in the three groups CON (control), CHO (cholesterol in diet) and CHO+EXTRACT (cholesterol in diet with *V. amygdalina* extract)**



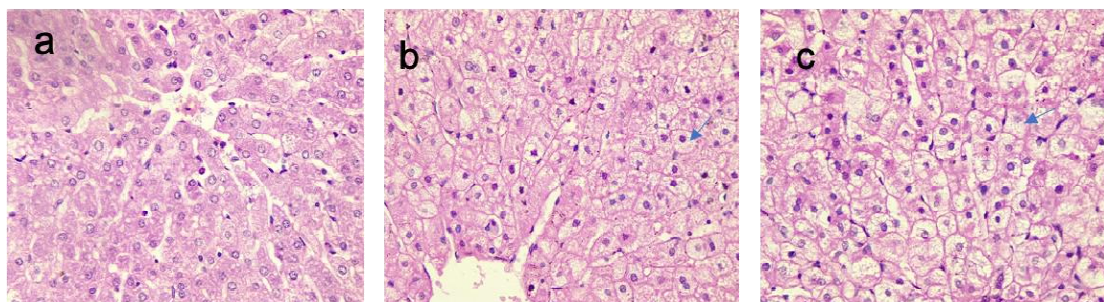
**Fig. 2. Box and whisker plot showing the summary of the MDA result of the animals in the three groups CON (control), CHO (cholesterol in diet) and CHO+EXTRACT (cholesterol in diet with *V. amygdalina* extract)**



**Fig. 3. Box and whisker plot showing the summary of the ALT result of the animals in the three groups CON (control), CHO (cholesterol in diet) and CHO+EXTRACT (cholesterol in diet with *V. amygdalina* extract)**



**Fig. 4. Box and whisker plot showing the summary of the AST result of the animals in the three groups CON (control), CHO (cholesterol in diet) and CHO+EXTRACT (cholesterol in diet with *V. amygdalina* extract)**



**Fig. 5. Histological sections of liver from rabbits (x400 magnification) Hematoxylin and Eosin stain**

(a) liver from rabbit fed normal chow, hepatocytes appear normal (b) liver of rabbit fed a high cholesterol diet showing the presence of numerous lipid vesicles within the cytoplasm of hepatocytes (c) liver from rabbit fed a high cholesterol diet and aqueous extract of *V. amygdalina* 200mg/kg daily for 12 weeks shows hepatocytes with numerous lipid vesicles in the cytoplasm. The blue arrows show vesicles and large hepatocytes

#### 4. DISCUSSION

Previous studies have demonstrated the antioxidant and lipid lowering effects of *V. amygdalina* extracts in rat. We hypothesized that aqueous extract of *V. amygdalina* will have an ameliorating effect on the liver enzymes, antioxidant levels and histological architecture of the liver of rabbits fed a high cholesterol diet.

There was no significant difference across the three groups in terms of the ALT values, however AST was significantly elevated in the animals that had high cholesterol diet (without extract) compared to animals on normal diet. Furthermore, comparison between the two groups of animals on high cholesterol diet revealed that the AST was reduced in animals that had extract compared to those without, even though this was not statistically significant. Thus,

the administration of the extract of *V. amygdalina* appears to have had an ameliorating effect on the level of AST liver enzymes even though it does not meet the criteria for statistical significance.

Another study reported an improvement in ALT and AST [16] with extract administration but the experiment was conducted on rats. In another study, carbon tetrachloride induced liver damage and aqueous extract of *V. amygdalina* resulted in amelioration of the increased liver enzymes ALT and AST [21,22]. The difference in the animal models used may account for the difference in the results obtained because the animals may have metabolized the extracts differently. Another explanation for the different liver function outcome may be that the referenced study [16] used methanol extract of *V. amygdalina*, unlike this study which utilized aqueous based extract. These differences may have resulted in differential fractions extracted from the leaves. Increasing the sample size in this study may have resulted in finding significant difference in small effect of the use of the extract.

MDA is a product of fatty acid peroxidation which increases in the presence of free radicals. A high fat or high cholesterol diet results in oxidative stress [23] and associated increased in MDA levels in the system. The level of MDA was not statistically different across the three experimental groups. Other studies investigated rats fed a high fat diet and found elevated MDA [24, 25]. The MDA level was not affected by high lipid diet in rabbits even though other studies in rats yielded increased levels. This is probably because the metabolism of lipids is different in these two species of experimental animals.

Compared to the rabbits on normal diet, SOD levels in the liver homogenate was reduced in the animals on high cholesterol diet. This difference was not statistically significant between the control group and the animals on high cholesterol diet alone (without extract). However, there was significantly reduced levels in SOD in the extract group compared to the control. The two groups of animals on high cholesterol diet didn't have significantly different levels of SOD, though the level was lower in animals on extract. SOD is an enzyme that converts super oxide free radicals to oxygen and hydrogen peroxide thus eliminating a potentially harmful material in the system. A reduction in SOD is associated with increased vulnerability to oxidative stress [26]. This study shows the

animals with reduced SOD also had signs of hepatic injury. Similarly, other studies [24, 27] found a reduction in the level of SOD in rats following a high fat, high cholesterol diet. In contrast to this finding, another group of researchers reported a significant increase in serum SOD displaying an ameliorative effect in irradiated rats given 800 mg/kg of methanolic extract of *V. amygdalina* [16]. The use of methanol extract may have requested in a different fraction of extract phytochemicals, they utilized a higher dose of extract and, the animal species used was rats. In addition, the injurious agent utilized in that experiment was irradiation versus a high lipid diet in this study, therefore the precise pathways of injury and amelioration are likely to be different.

The differences between this study and previous studies may be the fact that the experimental animals are different (rabbits versus rats), and the metabolism of dietary cholesterol is different, hence its effects on the levels of antioxidants and the product of lipid peroxidation. A study that examined the metabolites of cannabinoids found different levels of fractions in rats and rabbits [28]. Another study [29] also found difference between the two species in the metabolism of ethylene glycol. Another study identified differential response to agents used to induce hepatic cytochrome enzyme in rats compared to rabbits [30]. Although we didn't identify the exact metabolic pathways involved, this difference in animal species may be responsible for the lack of amelioration effects of high lipid diet in rabbits. The metabolism of the extract may also be different in these two species of animals. In addition, the use of methanolic extract in one of these experiments [16] probably resulted in a difference in the fraction of extract obtained from the leaves.

Furthermore, some studies in rabbits examined the effect of high cholesterol diets in rabbits and found a significant reduction in SOD [31,32] which is concordance to the results in this study. A study that showed an increase in MDA [32] in rabbits utilized dietary cholesterol at higher concentration in the diet compared to this study using 1% w/w in contrast to this study where 0.5% w/w was utilized.

The histological examination of the liver revealed normal liver architecture in animals from the control group. The features of hepatic steatosis was observed in the two groups of animals on high cholesterol diet. The relative weight of the

liver was also significantly higher in the two groups of animals on high cholesterol diet compared to the control group. This increased relative liver weight is probably because the animals in these two groups had hepatic steatosis. The increase in liver relative weight was not significantly different between the groups with and without extract administration. The finding of fatty liver changes following a high cholesterol diet is concordant with previous animal studies [33, 34]. A previous study that examined the protective effect of *V. amygdalina* extract utilized methanol extract in carbon tetrachloride injury and found the extract to be beneficial. The differences between these two studies namely, different species of animals (rat versus rabbit), different solvents of extraction and different injurious agents (Carbon Tetrachloride versus high cholesterol diet) are probably contributory to the different impact of the extract.

## 5. CONCLUSION

This study revealed that the use of atherogenic diet resulted in signs of hepatic injury and increased levels of the antioxidant superoxide dismutase. However, the use of 200mg/kg of aqueous extract of *V. amygdalina* did not appear to exert a statistically significant effect on the serum liver enzymes and markers of oxidative stress. It does not appear to have exerted any beneficial effect on the histology of the liver. Furthermore, the results from this study may be a pointer that the metabolism of extract may be different in different species of animals. Thus, highlighting the need for caution in extrapolating the results obtained in animal experiments to the effect the same substances will have in humans or other species of animals.

## 7. LIMITATIONS

The choice of dose of the extract used in this study was based on the dose used in previous studies that were conducted on rats. A pilot study to obtain a LD50 would have been beneficial. In addition, the use of other solvents for extraction may yield other fractions of phytochemicals that may be beneficial for ameliorating the effects of high cholesterol diets in rabbits.

## ETHICAL APPROVAL

This study was carried out with the approval of the University of Ibadan Ethical Committee on Experimental animals. The 'Principles of laboratory animal care' as contains in NIH

publication No. 85-23 revised 1985 were duly observed by the authors.

## ACKNOWLEDGEMENT

The authors thank Dr G. O. Ogun of the Pathology Department, University of Ibadan for his assistance in the conduction of this study.

## COMPETING INTERESTS

Authors have declared that no competing interests exist.

## REFERENCES

1. Donnelly KL, Smith CI, Schwarzenberg SJ, Jessurun J, Boldt MD, Parks EJ. Sources of fatty acids stored in liver and secreted via lipoproteins in patients with nonalcoholic fatty liver disease. *J Clin Invest.* 2005;115(5):1343-51. Available: <https://doi.org/10.1172/jci23621>
2. Wobser H, Dorn C, Weiss TS, Amann T, Bollheimer C, Büttner R, Schölmerich J, Hellerbrand C. Lipid accumulation in hepatocytes induces fibrogenic activation of hepatic stellate cells. *Cell Res.* 2009;19(8):996-1005. Available: <https://doi.org/10.1038/cr.2009.73>
3. Dowman JK, Tomlinson JW, Newsome PN. Pathogenesis of non-alcoholic fatty liver disease. *QJM.* 2010;103(2):71-83. Available: <https://doi.org/10.1093/qjmed/hc> p158
4. Marchesini G, Brizi M, Morselli-Labate AM, Bianchi G, Bugianesi E, McCullough AJ, Forlani G, Melchionda N. Association of nonalcoholic fatty liver disease with insulin resistance. *Am J Med.* 1999;107(5):450-5. Available: [https://doi.org/10.1016/s0002-9343\(99\)00271-5](https://doi.org/10.1016/s0002-9343(99)00271-5)
5. Fan JG, Cao HX. Role of diet and nutritional management in non-alcoholic fatty liver disease. *J Gastroenterol Hepatol.* 2013;28 (Suppl 4):81-7. Available: <https://doi.org/10.1111/jgh.12244>
6. Ye P, Cheah IK, Halliwell B. A high-fat and cholesterol diet causes fatty liver in guinea pigs. The role of iron and oxidative damage. *Free Radic Res.* 2013;47(8):602-13. Available: <https://doi.org/10.3109/10715762.2013.806796>
7. Day CP, James OF. Steatohepatitis: a tale of two "hits"? *Gastroenterology.* 1998;114(4):842-5.



- Available:[https://doi.org/10.1016/s0016-5085\(98\)70599-2](https://doi.org/10.1016/s0016-5085(98)70599-2)
8. Adams LA, Lymp JF, St Sauver J, Sanderson SO, Lindor KD, Feldstein A, Angulo P. The natural history of nonalcoholic fatty liver disease: a population-based cohort study. *Gastroenterology*. 2005;129(1):113-21. Available:<https://doi.org/10.1053/j.gastro.2005.04.014>
  9. Bedossa P. Pathology of non-alcoholic fatty liver disease. *Liver Int*. 2017;37 Suppl 1:85-89. Available:<https://doi.org/10.1111/liv.13301>
  10. Organizacion mundial de la salud. 2017. '1] WHO Congress on Traditional Medicine. 7-9 November 2008, Beijing, China'. WHO. Retrieved 20 September, 2020 Available:<https://www.who.int/traditional-complementary-integrative-medicine/about/beijing-congress/en/>
  11. Adia MM, Anywar G, Byamukama R, Kamatenesi-Mugisha M, Sekagya Y, Kakudidi EK, Kiremire BT. Medicinal plants used in malaria treatment by Prometra herbalists in Uganda. *J Ethnopharmacol*. 2014;155(1):580-8. Available:<https://doi.org/10.1016/j.jep.2014.05.060>
  12. Mohd Abd Razak MR, Afzan A, Ali R, Amir Jalaluddin NF, Wasiman MI, Shiekh Zahari SH, Abdullah NR, Ismail Z. Effect of selected local medicinal plants on the asexual blood stage of chloroquine resistant Plasmodium falciparum. *BMC Complement Altern Med*. 2014;14:492. Available:<http://doi.org/10.1186/1472-6882-14-492>
  13. Erasto P, Grierson DS, Afolayan AJ. Bioactive sesquiterpene lactones from the leaves of Vernonia amygdalina. *J Ethnopharmacol*. 2006;106(1):117-20. Available:<https://doi.org/10.1016/j.jep.2005.12.016>
  14. Akinpelu DA. Antimicrobial activity of Vernonia amygdalina leaves. *Fitoterapia*. 1999;70(4):432-434. Available:[https://doi.org/10.1016/S0367-326X\(99\)00061-1](https://doi.org/10.1016/S0367-326X(99)00061-1)
  15. Nwanjo HU. Efficacy of aqueous leaf extract of vernonia amygdalina on plasma lipoprotein and oxidative status in diabetic rat models. *Niger J Physiol Sci*. 2005;20(1-2):39-42.
  16. Adaramoye O, Ogungbenro B, Anyaegbu O, Fafunso M. Protective effects of extracts of Vernonia amygdalina, Hibiscus sabdariffa and vitamin C against radiation-induced liver damage in rats. *J Radiat Res*. 2008;49(2):123-31. Available:<https://doi.org/10.1269/jrr.07062>
  17. Zulli A, Hare DL. High dietary methionine plus cholesterol stimulates early atherosclerosis and late fibrous cap development which is associated with a decrease in GRP78 positive plaque cells. *Int J Exp Pathol*. 2009;90(3):311-20. Available:<https://doi.org/10.1111/j.1365-2613.2009.00649.x>
  18. Abdulmalik O, Oladapo OO, Bolaji MO. Effect of aqueous extract of Vernonia amygdalina on atherosclerosis in rabbits. *ARYA Atheroscler*. 2016;12(1):35-40. Available:<http://www.ncbi.nlm.nih.gov/pmc/articles/pmc4834179/>
  19. Ohkawa H, Ohishi N, Yagi K. Assay for lipid peroxides in animal tissues by thiobarbituric acid reaction. *Anal Biochem*. 1979;95(2):351-8. Available:[https://doi.org/10.1016/0003-2697\(79\)90738-3](https://doi.org/10.1016/0003-2697(79)90738-3)
  20. Valerino DM, McCormack JJ. Xanthine oxidase-mediated oxidation of epinephrine. *Biochem Pharmacol*. 1971;20(1):47-55. Available:[https://doi.org/10.1016/0006-2952\(71\)90470-9](https://doi.org/10.1016/0006-2952(71)90470-9)
  21. Arhoghro EM, Ekpo KE, Anosike EO, Ibeh GO. Effect of aqueous extract of bitter leaf (Vernonia Amygdalina Del) on Carbon Tetrachloride (CCl4) Induced Liver Damage in Albino Wistar Rats. *Eur. J. Sci. Res*. 2009;26:122-130.
  22. Adesanoye OA, Farombi EO. Hepatoprotective effects of Vernonia amygdalina (astereaceae) in rats treated with carbon tetrachloride. *Exp Toxicol Pathol*. 2010;62(2):197-206. Available:<https://doi.org/10.1016/j.etp.2009.05.008>
  23. Abdelmegeed MA, Banerjee A, Yoo SH, Jang S, Gonzalez FJ, Song BJ. Critical role of cytochrome P450 2E1 (CYP2E1) in the development of high fat-induced non-alcoholic steatohepatitis. *J Hepatol*. 2012;57(4):860-6. Available:<https://doi.org/10.1016/j.jhep.2012.05.019>
  24. Wang YX, Li Y, Sun AM, Wang FJ, Yu GP. Hypolipidemic and antioxidative effects of aqueous enzymatic extract from rice bran in rats fed a high-fat and -cholesterol diet. *Nutrients*. 2014;6(9):3696-710. Available:<https://doi.org/10.3390/nu6093696>

25. Tuzcu Z, Orhan C, Sahin N, Juturu V, Sahin K. Cinnamon polyphenol extract inhibits hyperlipidemia and inflammation by modulation of transcription factors in high-fat diet-fed rats. *Oxid Med Cell Longev*. 2017;2017:1583098. Available: <https://doi.org/10.1155/2017/1583098>
26. Johnson F, Giulivi C. Superoxide dismutases and their impact upon human health. *Mol Aspects Med*. 2005;26(4-5):340-52. Available: <https://doi.org/10.1016/j.mam.2005.07.006>
27. Surapaneni KM, Jainu M. Comparative effect of pioglitazone, quercetin and hydroxy citric acid on the status of lipid peroxidation and antioxidants in experimental non-alcoholic steatohepatitis. *J Physiol Pharmacol*. 2014;65(1):67-74.
28. Brown NK, Harvey DJ. In vitro metabolism of cannabiniol in rat, mouse, rabbit, guinea pig, hamster, gerbil and cat. *Eur J Drug Metab Pharmacokinet*. 1990;15(3):253-8. Available: <https://doi.org/10.1007/bf03190212>
29. Booth ED, Dofferhoff O, Boogaard PJ, Watson WP. Comparison of the metabolism of ethylene glycol and glycolic acid in vitro by precision-cut tissue slices from female rat, rabbit and human liver. *Xenobiotica*. 2004;34(1):31-48. Available: <https://doi.org/10.1080/00498250310001624636>
30. Kocarek TA, Schuetz EG, Strom SC, Fisher RA, Guzelian PS. Comparative analysis of cytochrome P4503A induction in primary cultures of rat, rabbit, and human hepatocytes. *Drug Metab Dispos*. 1995;23(3):415-21.
31. Janeesh PA, Abraham A. Amelioration of cholesterol induced atherosclerosis by normalizing gene expression, cholesterol profile and antioxidant enzymes by *Vigna unguiculata*. *Plant Foods Hum Nutr*. 2013;68(2):118-23. Available: <https://doi.org/10.1007/s11130-013-0345-1>
32. Ozturk B, Ozer O, Durak ZE, Billur D, Kizil S, Durak I, Ozturk HS. High cholesterol diet leads to oxidant load and peroxidation in the rabbit kidney tissue. *Bratisl Lek Listy*. 2016;117(4):235-41. Available: [https://doi.org/10.4149/bll\\_2016\\_045](https://doi.org/10.4149/bll_2016_045)
33. Lu JH, Hsia K, Lin CH, Chen CC, Yang HY, Lin MH. Dietary Supplementation with Hazelnut Oil Reduces Serum Hyperlipidemia and Ameliorates the Progression of Nonalcoholic Fatty Liver Disease in Hamsters Fed a High-Cholesterol Diet. *Nutrients*. 2019;11(9):2224. Available: <https://doi.org/10.3390/nu11092224>
34. Taylor E, Huang N, Bodde J, Ellison A, Killiany R, Bachschmid MM, Hamilton J. MRI of atherosclerosis and fatty liver disease in cholesterol fed rabbits. *J Transl Med*. 2018;16(1):215. DOI: 10.1186/s12967-018-1587-3 Available: <https://doi.org/10.1186/s12967-018-1587-3>

© 2020 Abdulmalik and Oladapo; This is an Open Access article distributed under the terms of the Creative Commons Attribution License (<http://creativecommons.org/licenses/by/4.0>), which permits unrestricted use, distribution, and reproduction in any medium, provided the original work is properly cited.

*Peer-review history:*

*The peer review history for this paper can be accessed here:*  
<http://www.sdiarticle4.com/review-history/63158>