



## Thinking beyond Tuberculosis: A Case Report

**Tauheed Ahmed<sup>1\*</sup>, Sanjay Khator<sup>2</sup>, Sangita D Kamath<sup>1</sup>  
and Rudra Prasad Samanta<sup>2</sup>**

<sup>1</sup>Department of Medicine, Tata Main Hospital, Jamshedpur, India.

<sup>2</sup>Department of Pulmonology, Tata Main Hospital, Jamshedpur, India.

### **Authors' contributions**

*This work was carried out in collaboration with all authors. Author TA was involved in the conception and design of the article, and writing the first draft of the manuscript. Author SK established the plan of the article, supervised the work and was responsible for diagnosis and management of the case. Author SDK was involved in drafting the manuscript, literature review and editing and approval of the final version. Author RPS was involved in the design of the article, interpretation of radiographic images and critically revising the manuscript. All authors read and approved the final manuscript.*

### **Article Information**

DOI: 10.9734/JAMMR/2020/v32i2330725

#### Editor(s):

(1) Dr. Chan-Min Liu, Xuzhou Normal University, P. R. China.

#### Reviewers:

(1) Narges Obeidi, Bushehr University of Medical Sciences, Iran.

(2) Prabin Shrestha, Tribhuvan University, Nepal.

Complete Peer review History: <http://www.sdiarticle4.com/review-history/63204>

**Case Study**

**Received 15 September 2020**

**Accepted 21 November 2020**

**Published 10 December 2020**

### **ABSTRACT**

Aspergilloma describes the saprophytic colonization of an area of devitalized lung tissue. It usually develops in pre-existing pulmonary cavities caused by tuberculosis, sarcoidosis and other such conditions. It is found in almost 15% to 25% of patients with cavitary lesions resulting from tuberculosis. In developing countries with high prevalence of tuberculosis, like India, aspergilloma is often misdiagnosed as tuberculosis. Hemoptysis is often equated with TB, and most patients are diagnosed clinically. Here we report one such case of a 56 year old male patient with past history of tuberculosis, who was initially diagnosed and being treated as a relapse of tuberculosis on the basis of hemoptysis and chest radiograph findings, till further detailed investigations revealed an aspergilloma in a post tubercular cavity as the cause of his symptoms.

**Keywords:** Aspergilloma; tuberculosis; hemoptysis; itraconazole.

\*Corresponding author: E-mail: tauheed.90@gmail.com;

## ABBREVIATIONS

ABPA- Allergic bronchopulmonary aspergillosis; CPA- Chronic pulmonary aspergillosis; CT- Computed tomography; TB- Tuberculosis; MTB- Mycobacterium tuberculosis.

## 1. INTRODUCTION

Aspergillus causes a spectrum of diseases in humans depending on the immune status of the host, ranging from hypersensitivity pneumonitis, ABPA, aspergilloma to invasive aspergillosis. Aspergillomas are fungal balls composed of *Aspergillus fumigatus* and are a non-invasive form of pulmonary aspergillosis. Aspergillomas may occur in patients with structurally abnormal lungs with pre-existing cavities, even in the presence of normal immunity [1].

Aspergilloma usually occurs in pre-existing lung cavities resulting from tuberculosis, sarcoidosis, and other conditions [2]. 25-80% of cases occur in pre-existing cavities due to tuberculosis. Aspergillomas normally colonize the upper lobes, where most cavities form. Most aspergillomas are asymptomatic. Others may present with cough, wheezing, mild fatigue and hemoptysis. Hemoptysis is typically infrequent and mild, but it occasionally can be massive or even life threatening.

Since the location (upper lobes) and clinical features such as cough and hemoptysis are similar in both tuberculosis and aspergilloma, many patients with aspergilloma are misdiagnosed as tuberculosis. This is especially true in countries with a high burden of tuberculosis such as India. In low resource settings, patients are often diagnosed clinically and started on anti tuberculous therapy, without any subsequent respite in their symptoms and often with toxicities from such prolonged therapy. The potential effects of chronic pulmonary aspergillosis after pulmonary tuberculosis have only recently been appreciated. These include life-threatening hemoptysis, misdiagnosis as smear-negative tuberculosis, and general exacerbation of posttuberculosis morbidity [3].

Our case report endeavours to highlight the same, so that clinicians may be more aware while treating such cases and always 'Think beyond Tuberculosis'.

## 2. CASE REPORT

A 56 year old male was admitted to Tata Main Hospital, Jamshedpur with complaints of cough, productive of blood mixed sputum on and off for the past 9 months. He reported no history of fever, night sweats, chest pain or weight loss. On

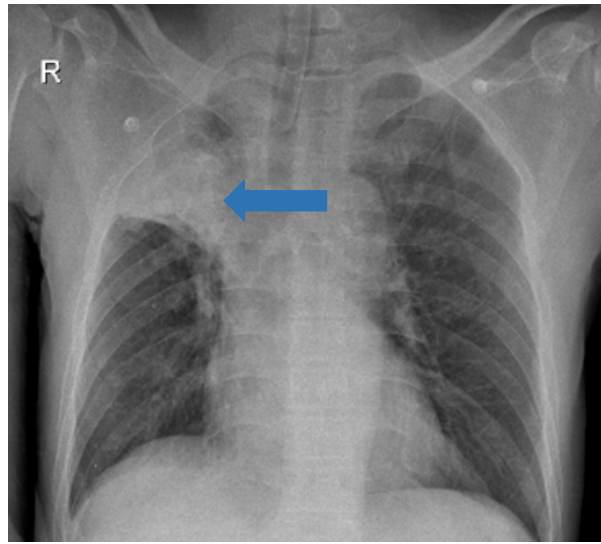
the day of admission to hospital, he had an episode of coughing out large amount of blood followed by breathing difficulty.

Patient was in severe respiratory distress when he presented to emergency and had to be intubated and resuscitated. After the initial episode, patient's condition improved and was extubated on the first day of inpatient stay. He was further maintained on oxygen support through face mask.

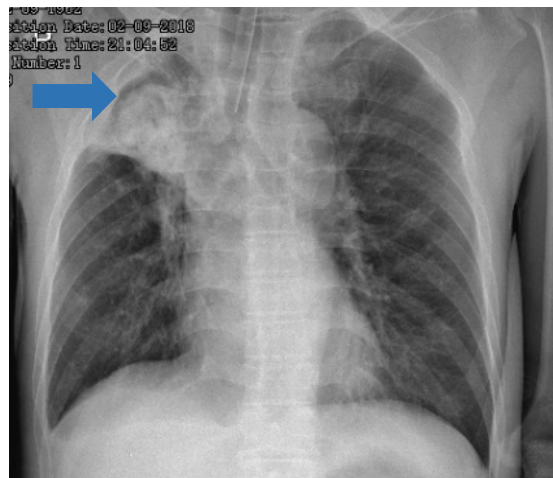
He had a history of pulmonary tuberculosis twelve years back for which he had taken anti-tubercular drugs for 6 months. There was no history of any other chronic illness such as diabetes, hypertension or asthma.

Almost 3 months after the cough started the patient noticed blood mixed sputum with the cough. Initially this occurred with less frequency occurring once or twice a week but this gradually progressed to a daily occurrence for which he consulted a local doctor and was advised a chest radiograph. Although sputum for acid fast bacilli was negative, due to a high index of clinical suspicion keeping in mind his past history and suggestive radiographic findings, patient was started on WHO category 1 anti-tubercular treatment. However, after 2 months of anti-tubercular treatment his symptoms of cough and hemoptysis persisted. A repeat chest radiograph revealed an opacity in right upper zone (Fig. 1).

Patient continued anti-tubercular therapy until his current admission. On examination he was coherent, afebrile and pale. Blood pressure was 112/74 mm Hg and pulse 108/minute. Chest examination revealed crepitations with cavernous breath sounds over right mammary area. Other areas had vesicular breath sounds with no added sounds. Examination of other systems was normal. Laboratory investigations revealed haemoglobin 6.6 gm/dl, leucocyte count-8700 per cu.mm, platelets 229000 per cumm, PT/INR-11.2/0.93, aPTT- 28secs, ESR-84mm. Sputum for acid fast bacilli and Gram stain were unrevealing. Sputum CBNAAT- MTB (*Mycobacterium Tuberculosis*) not detected. Fungal culture of sputum did not show any growth. Chest radiograph done on admission revealed an opacity in right upper zone with an air crescent over the opacity with a tracheal shift to the right (Fig. 2).



**Fig. 1. Chest radiograph 7 months prior to the current admission showing an opacity in right upper zone (arrow)**



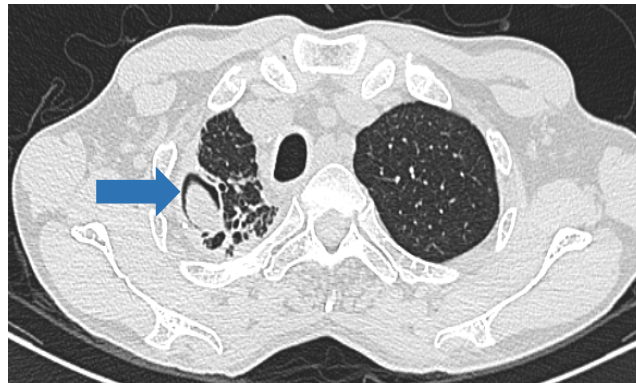
**Fig. 2. Chest radiograph on current admission with arrow showing an air crescent over an inhomogenous opacity in right upper zone (Monod sign)**

Suspecting aspergilloma from chest radiograph, Computed tomography (CT) of thorax and IgG antibody against aspergillus antigen were advised.

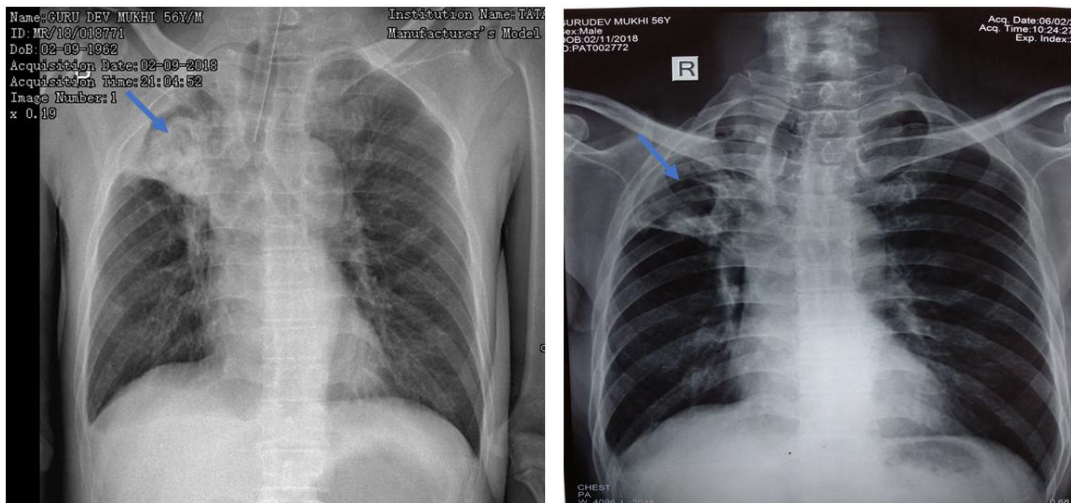
CT thorax (Fig. 3) revealed the presence of a cavity in the right apical lobe with a homogenous opacity in the dependent position which was suggestive of a fungal ball. Antibody against *Aspergillus* antigen were positive ( $>12$  U/ml). Diagnosis of Aspergilloma was thus, confirmed and patient was started on itraconazole 200 mg twice daily. He also received packed cell transfusion, intravenous antibiotics and other

supportive care. Patient was further discharged and advised to continue oral itraconazole 200 mg twice daily for a year. He was kept on regular follow up. A chest radiograph and CT thorax was repeated after 6 months (Figs. 4 and 5).

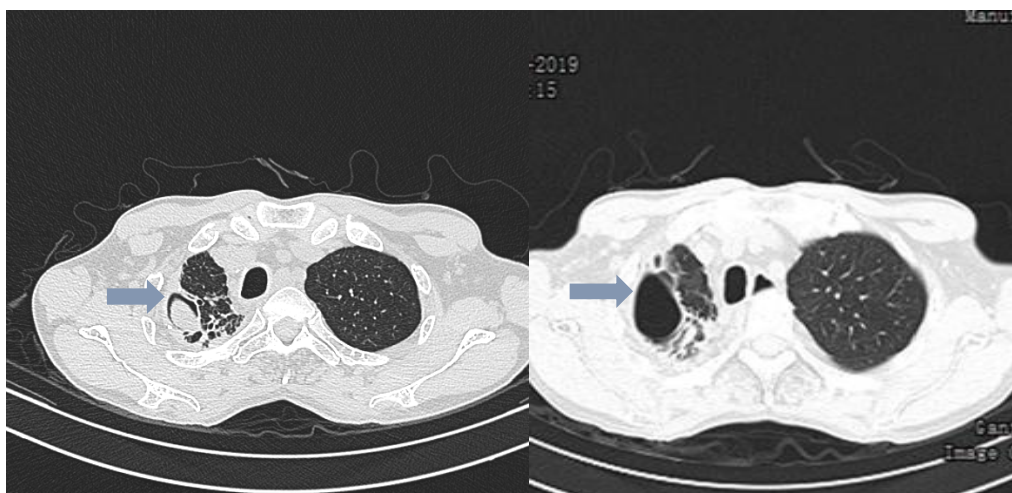
In the repeat computed tomography as shown in Fig. 5, the cavity persists but the fungal ball which was present in the previous CT has completely disappeared. Also, the patient had improved symptomatically with no further cough or hemoptysis. Therefore, this was a case of Aspergilloma which was being treated as a relapse of tuberculosis.



**Fig. 3.** Axial CT Thorax on admission showing a cavity in the right apical lobe with a round soft tissue lesion in the dependent position (shown by arrow)



**Fig. 4.** Comparative chest radiograph after 6 months. Image on the right shows clearing of the opacity within the cavity (shown by arrows)



**Fig. 5.** Comparative CT Thorax after 6 months. Image on the right shows disappearance of the fungal ball as seen in previous CT (shown by arrows)

### 3. DISCUSSION

Aspergilloma is an often underdiagnosed entity. In the case described above, a patient was being incorrectly treated as a recurrence of pulmonary tuberculosis, where in fact it was an aspergilloma lung in a post tubercular cavity, mimicking tuberculosis. When misdiagnosed, pulmonary aspergillosis may lead to untoward consequences such as life-threatening hemoptysis and a general exacerbation of posttuberculosis morbidity.

Aspergillomas develop in approximately 15% to 25% of patients with cavitary lesions in lungs resulting from tuberculosis [4]. It occurs in up to 20% of residual pulmonary cavities  $\geq 2.5$  cm in diameter [3].

Aspergillomas are usually present in the upper lobes, which is where most cavities form. Most aspergillomas are asymptomatic. Others may present with cough, wheezing, mild fatigue and hemoptysis. Hemoptysis is typically infrequent and mild, but it occasionally can be massive or even life threatening [5]. The prevalence of clinically significant haemoptysis is associated with the size of cavity and mass of aspergilloma [6].

Diagnosis is based on:

- i. Clinical and chest radiographic features, along with
- ii. Serologic evidence of precipitating antibodies to *Aspergillus* species

Sputum cultures are positive for *Aspergillus* in only around 50% of patients. As such it is not a sensitive and specific diagnostic marker. Precipitating antibodies to *Aspergillus* antigens are found in more than 90 percent of patients with aspergilloma [7]. Due to a lack of controlled studies, there is no consensus on the treatment of aspergilloma. Management options for aspergilloma currently include 1. Surgical resection. 2. Systemic or local administration of antifungal agents 3. Conservative management with careful follow-up.

Among systemic antifungals, itraconazole is currently the preferred antifungal drug for chronic and allergic forms of aspergillosis including aspergilloma. It is orally administered and has high tissue penetration into the lung. Several non-controlled studies have reported on the use of itraconazole for aspergilloma. These

studies have demonstrated that itraconazole at doses of 200 to 400 mg/day for 6 to 18 months resulted in symptomatic and radiographic improvement in almost two-thirds of the patients [5]. This result was also seen in our patient with symptomatic and radiological clearance of the disease process in a period of 6 months.

A significant limitation of itraconazole is that it works slowly. Recurrence of aspergilloma may follow discontinuation of itraconazole treatment. Another concern when using itraconazole is an increasing rate of antifungal resistance [8]. Voriconazole or posaconazole can be substituted when failure, emergence of resistance, or adverse events occur.

A study done by, Gupta et al. [9]. in 2015 presents the results of a randomized trial on the role of itraconazole in treating patients with pulmonary aspergillomas (PA). 60 patients were treated with itraconazole for a period of 12 months. The results of this study highlighted that the medical management of aspergilloma with itraconazole is both effective and feasible. Good clinical (93.8%) and radiological responses (73.4%) were seen in the patients, at the end of 12 months [9].

*Aspergilloma and Tuberculosis:* In countries with a current or prior high burden of tuberculosis, such as India, a cavity resulting from previous tuberculosis is the most common cause of aspergilloma [10].

CPA complicates tuberculosis frequently enough to represent a global public health issue. A study by Jain et al. [11] in 2018, found that chronic pulmonary aspergillosis (CPA) complicates 4.9–6.3% of all treated pulmonary TB cases. This has major implications for TB control programmes. It suggests that all patients with recurrent cough or haemoptysis following treatment of pulmonary TB, should be tested for CPA with *Aspergillus*-specific antibody tests. Further a CT thorax can be done to confirm the diagnosis in those with elevated antibody titres. Testing should also be routinely done in patients beginning empirical treatment for “smear-negative TB”. Aspergillomas, which constitute almost 25% of CPA cases [12], are often misdiagnosed as smear-negative or recurrent pulmonary tuberculosis [13]. Hemoptysis is often attributed to tuberculosis, and most patients are clinically diagnosed and started on anti-tubercular drugs. These patients continue anti tubercular drugs

without any benefit while suffering drug toxicities for prolonged periods.

This was also the case in our patient where he was started on anti-tubercular drugs after presenting with hemoptysis, which was actually due to an aspergilloma in a post tubercular cavity.

#### 4. CONCLUSION

Aspergilloma is an under recognized entity in India and often misdiagnosed as tuberculosis. It should be routinely considered in all patients with history of old treated pulmonary tuberculosis, who present with recurrent hemoptysis and are sputum negative for acid fast bacilli. Routine anti tubercular therapy to all such patients without proper evaluation should be avoided. Itraconazole has good activity against aspergillus and may be used for treatment of aspergilloma, with good efficacy and positive outcomes.

#### CONSENT

Written informed consent was obtained from the patient for publication of this case report and the accompanying images.

#### ETHICAL APPROVAL

As per international standard written ethical permission has been collected and preserved by the author(s).

#### COMPETING INTERESTS

Authors have declared that no competing interests exist.

#### REFERENCES

1. Ofori A, Steinmetz AR, Akaasi J, Asafu Adjaye Frimpong GA, Norman BR, Obeng-Baah J, et al. Pulmonary aspergilloma: An evasive disease. *Int J Mycobacteriology*. 2016;5(2):235–9.
2. Steinbach WJ. 244 - Aspergillus Species. In: Long SS, Prober CG, Fischer M, editors. *Principles and Practice of Pediatric Infectious Diseases (Fifth Edition)* [Internet]. Elsevier. 2018;1238-1244.e2. [cited 2020 Nov 14]. Available:<http://www.sciencedirect.com/science/article/pii/B9780323401814002449>
3. Denning D. Aspergillosis. In: Kasper DL, Fauci AS, Hauser SL, Longo DL, Jameson JL, Loscalzo J, editors. *Harrison's principles of internal medicine*. 19th ed. New York, NY: McGraw Hill Education. 2015;1345–9.
4. Aspergillus in persistent lung cavities after tuberculosis. A report from the research committee of the British Tuberculosis Association. *Tubercle*. 1968;49(1):1–11.
5. Chamilos G, Kontoyiannis DP. Aspergillus, candida and other opportunistic mold infections of the lung. In: Fishman's *Pulmonary diseases and disorders*. 4th ed. New York: McGraw Hill Education. 2008; 2291–325.
6. Lee J-K, Lee YJ, Park SS, Park JS, Cho Y-J, Park YS, et al. Clinical course and prognostic factors of pulmonary aspergilloma. *Respirology*. 2014;19(7): 1066–72.
7. Denning DW, Cadranel J, Beigelman-Aubry C, Ader F, Chakrabarti A, Blot S, et al. Chronic pulmonary aspergillosis: rationale and clinical guidelines for diagnosis and management. *Eur Respir J*. 2016;47(1):45–68.
8. Maturu VN, Agarwal R. Itraconazole in chronic pulmonary aspergillosis: In whom, for how long, and at what dose? *Lung India Off Organ Indian Chest Soc*. 2015; 32(4):309–12.
9. Gupta PR, Jain S, Kewlani JP. A comparative study of itraconazole in various dose schedules in the treatment of pulmonary aspergilloma in treated patients of pulmonary tuberculosis. *Lung India*. 2015;32(4):342.
10. Smith NL, Denning DW. Underlying conditions in chronic pulmonary aspergillosis including simple aspergilloma. *Eur Respir J*. 2011;37(4):865–72.
11. Page ID, Byanyima R, Hosmane S, Onyachi N, Opira C, Richardson M, et al. Chronic pulmonary aspergillosis commonly complicates treated pulmonary tuberculosis with residual cavitation. *Eur Respir J* [Internet]; 2019. [cited 2020 Nov 15]; Available:<https://erj.ersjournals.com/content/early/2019/01/02/13993003.01184-2018>
12. Felton TW, Baxter C, Moore CB, Roberts SA, Hope WW, Denning DW. Efficacy and

- safety of posaconazole for chronic pulmonary aspergillosis. Clin Infect Dis. 2010;51(12):1383–91.
13. WHO | Global burden of chronic pulmonary aspergillosis as a sequel to pulmonary tuberculosis [Internet]. WHO. World Health Organization. [cited 2020 Apr 15]. Available: <https://www.who.int/bulletin/volumes/89/12/11-089441/en/>

---

© 2020 Ahmed et al.; This is an Open Access article distributed under the terms of the Creative Commons Attribution License (<http://creativecommons.org/licenses/by/4.0>), which permits unrestricted use, distribution, and reproduction in any medium, provided the original work is properly cited.

*Peer-review history:*

*The peer review history for this paper can be accessed here:*  
<http://www.sdiarticle4.com/review-history/63204>