

Effect of Balloon Catheter Angioplasty Alone for Recurrent Bilateral Renal Artery Restenosis and Quick Deterioration for Hemodialysis: An Alternative for in-Stent Restenosis

Mariana Pezzute Lopes^{1*}, Caio Rebouças Fonseca Cafezeiro¹,
Daniela Calderaro¹, Luiz Junya Kajita¹, Luiz Aparecido Bortolotto¹,
Henrique C. Simbo Muela¹ and Thiago Andrade Macedo¹

¹Heart Institute, University of São Paulo, São Paulo, Brazil.

Authors' contributions

This work was carried out in collaboration among all authors. Authors MPL, CRFC, LAB and TAM described the case, adjust the figures and wrote the first draft of the manuscript. Author LJK performed the renal arteriography and angioplasty. Authors MPL, CRFC, DC, LAB, HCSM and TAM managed the literature searches. All authors read and approved the final manuscript.

Article Information

DOI: 10.9734/CA/2019/v8i230098

Editor(s):

(1) Dr. Francesco Pelliccia, Professor, Department of Heart and Great Vessels, University La Sapienza, Rome, Italy.

Reviewers:

(1) Mohamed Siddig Mohammed Ahmed Mulah, University of Aljuffrah, Libya.

(2) A. Romani, Case Western Reserve University, USA.

Complete Peer review History: <http://www.sdiarticle3.com/review-history/48678>

Case Report

Received 13 February 2019

Accepted 24 April 2019

Published 01 May 2019

ABSTRACT

Aim: Atherosclerotic renal artery stenosis is one of the main causes of secondary hypertension and results in a progressive loss of renal function. This case reports recurrent hypertensive pulmonary edema and worsening renal function successfully treated with multiple percutaneous renal interventions.

Presentation of the Case: A 62-year-old female patient was admitted for carotid endarterectomy. She had uncontrolled blood pressure and worsened renal function. Bilateral renal artery stenosis was diagnosed and endovascular procedure plus stent was performed in both renal arteries. She was discharged with an improvement in renal function and blood pressure. Three months later, she presented a sudden onset of pulmonary hypertensive edema. Renal arteriography confirmed

*Corresponding author: E-mail: mari.pezzutelopes@gmail.com;

bilateral in-stent restenosis and a new bilateral angioplasty plus stent was fulfilled. Six months later, new worsening of dyspnea, severe renal dysfunction, and new hospitalization were indicated renal replacement therapy. Renal arteriography showed again bilateral renal artery in-stent restenosis and bilateral balloon catheter angioplasty with no stent was performed. She was discharged, with no need for hemodialysis, improved blood pressure and proposal for further discussion about surgical revascularization.

Discussion: When severe reduction of glomerular filtration rate occurs in hypertensive patients with high risk for atherosclerotic disease, it seems prudent to examine renal arteries. Once a diagnosis is made, if blood pressure control cannot be achieved, mainly associated with progressive renal dysfunction, it is recommended restoration of renovascular supply.

Conclusion: Percutaneous renal intervention with no-stenting in bilateral in-stent restenosis and recent onset of hemodialysis may contribute to reversion of renal dysfunction even in patients undergoing to previous interventions.

Keywords: Renal artery stenosis; pulmonary hypertensive edema; hypertension; percutaneous renal intervention.

ABBREVIATIONS

ARAS : Atherosclerotic Renal Artery Stenosis

LICAS : Left internal Carotid Artery Stenosis

BP : Blood Pressure

ICU : Intensive Care Unit

GFR : Glomerular Filtration Rate

1. INTRODUCTION

Atherosclerotic renal artery stenosis (ARAS) remains one of the most prevalent and relevant causes of secondary hypertension [1]. Advanced age and atherosclerotic risk factors are associated with an increased prevalence of ARAS. Classic clinical clues that suggesting the diagnosis of ARAS include a significant increase in blood pressure levels after 50 years of age mainly in patients with no family history of hypertension; hypertension associated with renal insufficiency (especially if renal function worsens after the administration of an agent that blocks the renin-angiotensin-aldosterone system); hypertension associated with repeated hospital admissions for heart failure (hypertensive acute pulmonary edema), and resistant hypertension [2].

Advances in antihypertensive drug therapy and intensive risk factor management including statin therapy can improve clinical outcomes in many individuals. Despite these, timely recognition of vascular occlusive disease is important to avoid progressive renal functional loss [1]. Guidelines cite flash pulmonary edemas as an indication for renal artery revascularization in ARAS. Moreover, patients presenting with a combination of sudden declining kidney function and resistant

hypertension also may benefit from revascularization [3].

2. PRESENTATION OF THE CASE

A 62-year-old female was evaluated by a vascular surgical team because of asymptomatic left internal carotid artery stenosis (LICAS) greater than 70%. She had a history of insulin-dependent diabetes, resistant hypertension, and peripheral artery disease. The patient was admitted at the Hospital das Clinicas, Faculdade de Medicina, Universidade de Sao Paulo - Brazil, for performing endarterectomy for LICAS. She was evaluated preoperatively and the cardiology team identified an abdominal murmur suggestive of ARAS. Her serum creatinine had worsened from 1.8 to 2.7 mg/dL. Doppler ultrasonography of renal arteries was suggestive of bilateral renal artery stenosis. Percutaneous transluminal renal angioplasty was performed. Renal function progressively improved as well as blood pressure (BP). She was discharged with no performing endarterectomy at that time.

Six months later, she returned to the emergency department due to hypertensive acute pulmonary edema, BP of 240/120 mmHg and worsening renal function. Strict BP control (intravenous sodium nitroprusside), orotracheal intubation and hemodialysis were required. Renal angiography confirmed bilateral in-stent restenosis, being indicated bilateral stent angioplasty and new improvement of renal function was achieved. After 3 months of this hospitalization, she went back to the emergence of the Heart Institute reporting high BP and severe dyspnea. New hospital admission was carried out. She

presented oliguria and worsened systemic congestion, with no suitable response to diuretic therapy, and was referred to the intensive care unit. At this time, she needed hemodialysis and intravenous nitroglycerin. Renal angiography was again performed, showing again bilateral in-stent restenosis (Fig. 1) and bilateral balloon catheter angioplasty (without stent) was performed (Fig. 2). After the patient procedure, progressive improvement of renal function (creatinine 2.8 mg/dl) as well as BP with a smaller number of antihypertensive drugs. She was discharged with no need for new hemodialysis. Dual antiplatelet therapy (acetylsalicylic acid plus clopidogrel) and high potency statin were prescribed.

3. DISCUSSION

We described a case of bilateral artery stenosis with multiple interventions. Even in these patients, an appropriated procedure may improve renal function and reverse the need for

hemodialysis. When reduced glomerular filtration rate (GFR) and high risk of atherosclerotic disease are present mainly in hypertensive patients, it seems prudent to examine renal arteries. The choice of the best method for evaluation should according to the probability and severity of ARAS. Renal artery Doppler ultrasound may be useful in patients with elevated creatinine as there is no need to use contrast. Renal angiography is the gold standard for high-risk patients, even with reduced GFR, where selective renal artery catheterization should be indicated. Antihypertensive drug therapy should be managed progressively as needed to achieve the individual blood pressure target. If adequate BP cannot be achieved and/or high-risk conditions are present such as refractory hypertension, progressive renal dysfunction and/or episodes of circulatory congestion, it is recommended moving forward with characterization and restoration of the renal supply.

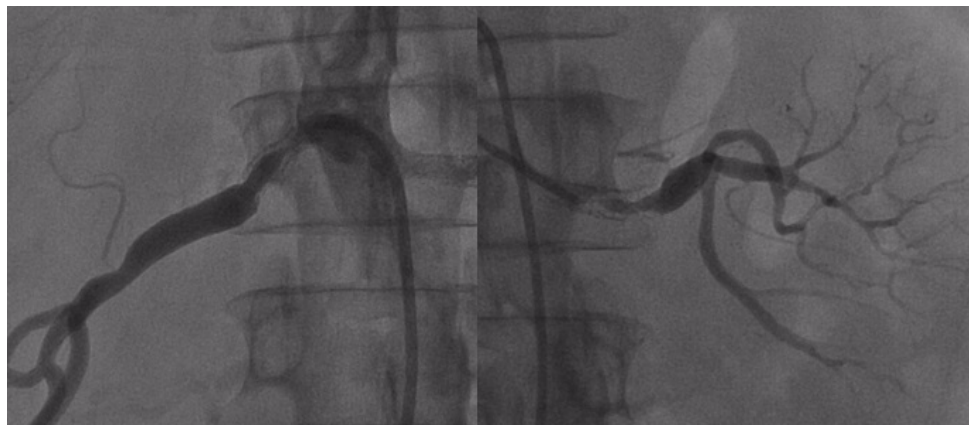


Fig. 1. Selective renal angiography showing bilateral in-stent restenosis

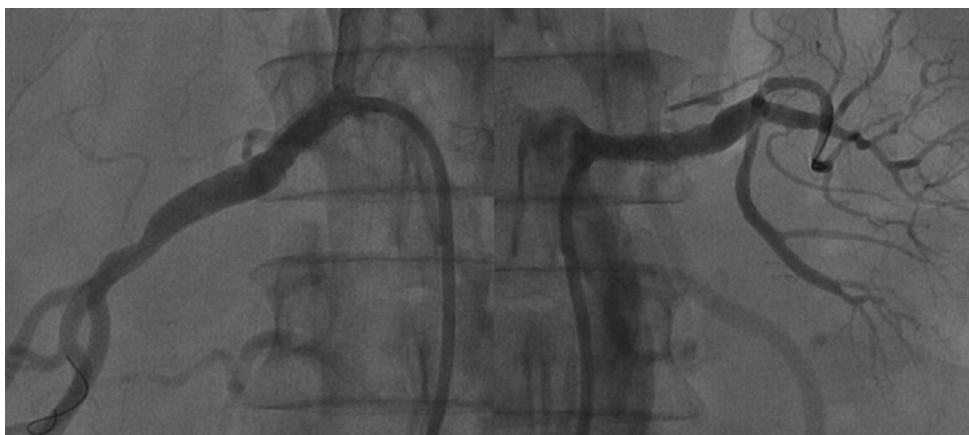

Fig. 2. Selective renal angiography after bilateral balloon catheter angioplasty

The development of endovascular interventional techniques has been an important advance in managing a renal vascular disease, being possible to restore vessel patency in the large majority of patients [4]. Nowadays, renal artery stent placement is a recognized treatment for patients with hemodynamically significant renal artery stenosis when medical therapy fails [5]. Since the widespread application of effective antihypertensive drug therapy and endovascular stents, surgical renal revascularization has been performed less commonly [6]. Among patients who have an indication for renal artery revascularization, a surgical procedure is indicated for selected patients who have complex anatomic lesions, associated with aortic disease and/or failed endovascular repair [7].

During the past decades, percutaneous renal artery stent placement has been increasing. In this way, renal artery stent stenosis became more frequent, reported as 25% rate after successful angioplasty [8]. Renal artery restenosis can develop in up to 14–18% of subjects followed for a year. Recommendations for follow-up include blood pressure evaluation associated with renal function and surveillance renal ultrasound as indicated. Some institutions favor antiplatelet agents such as clopidogrel for several months after stenting, although data are limited to support this [4,9]. In clinical practice, cases of resistant hypertension associated with reduced renal function and high cardiovascular risk, as in the case reported, it is prudent to proceed with renal artery percutaneous intervention. Although a solid evidence in literature regarding this type of intervention is scarce, it was decided not to use *stents* in this final approach because of the potential higher risk of intra stent thrombosis. In general, the earlier diagnosis may magnify the benefit of the procedure. Similarly, renal function deteriorating may be reversible or associated with persistent renal injury, despite restoration of renal perfusion [10]. As in this case, renal interventions, although late, can lead to an improvement in renal function and allow discharge without the need for hemodialysis.

4. CONCLUSION

Percutaneous renal intervention in a patient with bilateral RAS and recent onset of hemodialysis may have a favorable effect on the reversion of renal dysfunction, even in patients undergoing previous interventions and if angioplasty is performed with no use of a renal stent. In this

case, the choice of treatment was individualized to avoid worse renal outcomes. Subsequently, surgical renal revascularization may be the best treatment for this patient.

CONSENT

Written informed consent was obtained from the patient for publication of this case report and accompanying images.

ETHICAL APPROVAL

As per international standard or university standard was written ethical permission has been collected and preserved by the authors.

COMPETING INTERESTS

Authors have declared that no competing interests exist.

REFERENCES

1. Textor SC, Lerman L. Renovascular hypertension and ischemic nephropathy. *Am J Hypertens.* 2010;23:1159.
2. Dworkin LD, Cooper CJ. Clinical practice. Renal-artery stenosis. *N Engl J Med.* 2009;361:1972.
3. Ritchie J, Green D, Chrysochou C, Chalmers N, Foley RN, Kalra PA. High-risk clinical presentations in atherosclerotic renovascular disease: Prognosis and response to renal artery revascularization. *American Journal of Kidney Diseases.* 2014;63(2):186-197.
4. Sandra M. Herrmann, Stephen C. Textor. Current concepts in the treatment of renovascular hypertension. *American Journal of Hypertension.* 2018;31(2):139–149.
5. Chi YW, White CJ, Thornton S, Milani RV. Ultrasound velocity criteria for renal in-stent restenosis. *J Vasc Surg.* 2009;50: 119–123.
6. Murphy TP, Soares G, Kim M. Increase in the utilization of percutaneous renal artery interventions by Medicare beneficiaries, 1996-2000. *AJR Am J Roentgenol.* 2004;183:561.
7. Stanley JC, David M. Hume memorial lecture. Surgical treatment of renovascular hypertension. *Am J Surg.* 1997;174: 102.

8. Bax L, Woittiez AJ, Kouwenberg HJ, et al. Stent placement in patients with atherosclerotic renal artery stenosis and impaired renal function: A randomized trial. *Ann Intern Med.* 2009;150(12):840-848.
9. Boateng FK, Greco BA. Renal artery stenosis: Prevalence of, risk factors for, and management of in-stent stenosis. *Am J Kidney Dis.* 2013;61:147–160.
10. Eirin A, Gloviczki ML, Tang H, Gössl M, Jordan KL, Woollard JR, et al. Inflammatory and injury signals released from the post-stenotic human kidney. *Eur Heart J.* 2013;34:540–548a.

APPENDIX

	Before balloon catheter angioplasty	After balloon catheter angioplasty
Blood pressure, mmHg	240/120	130/80
Renal function (creatinine), mg/dL	6.1	2.8
Need for hemodialysis	Yes	No

© 2019 Lopes et al.; This is an Open Access article distributed under the terms of the Creative Commons Attribution License (<http://creativecommons.org/licenses/by/4.0>), which permits unrestricted use, distribution, and reproduction in any medium, provided the original work is properly cited.

Peer-review history:
The peer review history for this paper can be accessed here:
<http://www.sdiarticle3.com/review-history/48678>