

# B Lymphoblastic Lymphoma of Thigh: A Case of an Unusual Location

PALLAVI NAIR<sup>1</sup>, MT SUGEETH<sup>2</sup>, AV JAYASUDHA<sup>3</sup>

## ABSTRACT

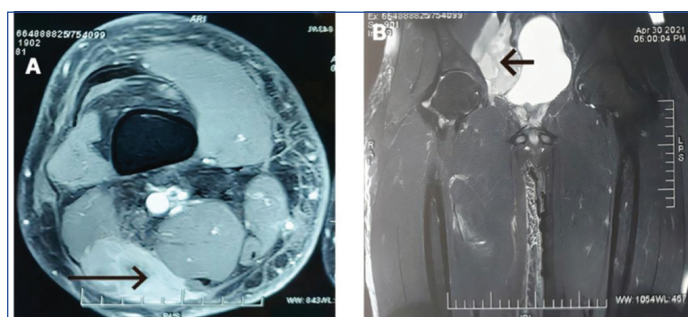
B-Lymphoblastic Lymphoma (B-LBL) is a malignancy of immature B lymphoid cells. They have a low propensity for bone marrow involvement. They typically present as generalised lymphadenopathy, bone lesions, mediastinal or skin lesions. They present with more skin and soft tissue involvement than acute lymphatic leukaemias. They are treated with systemic chemotherapy similar to their leukaemic counterparts. They have a favourable prognosis with a survival of 90%, although it worsens with age. Here, we present the case of a 23-year-old gentleman who was evaluated for a swelling in the posterior aspect of right thigh clinically resembling a sarcoma. Imaging studies showed a lesion in the posterior compartment of right thigh which showed contrast enhancement and hyperintensity in T2 images. Pelvic and inguinal node was enlarged. Ultrasound guided biopsy from the lymph node was suggestive of B-LBL. There was no bone marrow involvement. He was treated according to Berlin-Frankfurt-Munster (BFM) 95 protocol and attained remission post induction. He completed induction, consolidation and reinduction and is currently on maintenance treatment.

**Keywords:** Berlin-Frankfurt-Munster 95 protocol, Lymphoblastic lymphoma, Sarcoma, Thigh mass

## CASE REPORT

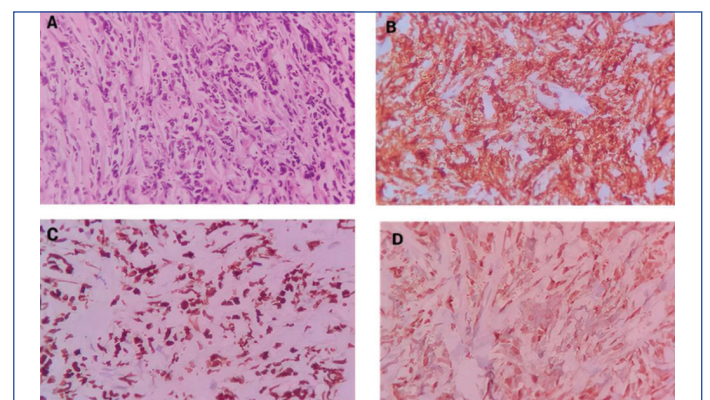
A 23-year-old man presented with painless swelling in the posterior aspect of right thigh with progressive increase in size of two months duration. There were no other swellings anywhere else in the body. On examination, he had a swelling in the posterior aspect of right thigh, 10×7×7 cm in size which was non tender, immobile, with ill-defined borders. It was associated with oedema of the right lower limb. There was no local rise in temperature or restriction of joint movements and there were no distal neurovascular deficits.

His haemogram showed Haemoglobin (Hb) of 13.4 g/dL, white blood cell count of 9100/mm<sup>3</sup> and platelet count of 3.73 L/mm<sup>3</sup> and serum biochemistry including Lactate Dehydrogenase (LDH) were within normal limits. Magnetic Resonance Imaging (MRI) scan of right thigh and abdomen showed a large 3.1×5.4×7.7 cm T1 isointense and T2 hyperintense lesion in the posterior compartment of right distal thigh with epicentre in intermuscular plane between distal biceps femoris and semitendinosus muscle with involvement of adjacent biceps femoris [Table/Fig-1a]. There was a right pelvic nodal mass measuring 7.4×5.7 cm causing compression of right external iliac and common femoral vessels along with multiple discrete external iliac and inguinal lymph nodes [Table/Fig-1b]. Radiologically, the lesion showed heterogenous contrast enhancement and was hyperintense in T2 weighed images which favoured a soft tissue sarcoma. Computed Tomography (CT) scan of thorax and neck was done as part of staging work-up and was within normal limits.



**[Table/Fig-1]:** a) MRI T2 contrast coronal section of right posterior thigh showing T2 hyperintense lesion (arrow) with epicentre in intermuscular plane between distal biceps femoris and semitendinosus muscle; b) MRI T2 contrast sagittal section showing right pelvic nodal mass (arrow).

Ultrasound guided biopsy was done from the lymph node mass and thigh swelling. Histopathology examination of the lymph node biopsy specimen showed atypical cells with round nuclei, finely dispersed chromatin, inconspicuous nucleoli and scant cytoplasm. On Immunohistochemistry (IHC) these cells were positive for terminal deoxynucleotidyl transferase (TdT), CD10, CD 20 and CD 79a and negative for CD7, CD3 epsilon, CD33, CD34, CD30, Leucocyte Common Antigen (LCA), Cytokeratin (CK), Desmin, MyoD1, and CD117 [Table/Fig-2]. Biopsy from the thigh swelling showed extensive crush artefact. Bone marrow study and Cerebrospinal Fluid (CSF) cytology were within normal limits. Fluorescence in situ hybridisation and reverse transcriptase polymerase chain reaction for BCR-ABL translocation were negative. Conventional cytogenetics done on bone marrow specimen revealed normal karyotype. He was started on BFM 95 protocol and attained remission after one month of induction chemotherapy [1]. Patient is now in remission and he completed induction, consolidation and reinduction phase of BFM 95 protocol.



**[Table/Fig-2]:** a) Microscopy section showing linear core of fibrocollagenous tissue infiltrate by atypical cells with extensive crush artefact, scanty cytoplasm and irregular nuclear membrane (X100); b) Atypical cells showing CD10 positivity (X100); c) PAX5 positivity (X100); d) Tdt positivity (X100 magnification).

## DISCUSSION

The LBL is a malignancy of immature lymphoid cells. They are the tissue counterparts of Acute Lymphoblastic Leukaemia (ALL) without significant peripheral blood and bone marrow involvement.

Among LBL, about 10% express B cell immunophenotype. It has a male predilection and is characterised by rapidly enlarging mass involving lymph nodes, skin, marrow or extra nodal sites [2]. B-LBL may involve other sites including head and neck, retroperitoneum, mediastinum, pleura, breast, ovary, genitourinary tract, kidneys, brain and soft tissue [3]. It is characterised by a higher incidence of skin involvement (33%) compared to acute lymphatic leukaemia (1%) [4]. Focal (<25%) or absent bone marrow or peripheral blood involvement distinguish it from B-Acute Lymphatic Leukaemia (B-ALL) [5]. T-LBL presents as mediastinal masses in 50% to 65% of cases compared to 4% in B-LBL [6]. The prognosis of patients with B-LBL is similar to that of patients with low-risk B-ALL and favourable subgroup of intermediate risk B-ALL. The neoplastic cells of B-LBL are small to medium size and are characterised by fine chromatin, inconspicuous nucleoli, and a high mitotic rate with background mature lymphocytes and plasma cells. LBL show positive periodic acid Schiff staining, variable positivity for non specific esterase and Sudan Black B, and negativity for myeloperoxidase. Tumour cells are positive for B cell markers like CD19, CD79a and CD22 and frequently express CD10 (Common acute lymphocytic leukaemia antigen, CALLA), CD24, PAX5, TdT [6]. CD20, CD34 and CD45 are variably expressed. They may also express CD99 which at one time was thought to be exclusive to Ewing family of tumours. About 30% of cases co-express myeloid antigens, mostly CD13 and CD33. The differential diagnosis for B-LBL include other small round cell neoplasms like T-LBL, blastoid variant of mantle cell lymphoma, malignant neoplasms of the small round blue cell category, myeloid sarcoma, Burkitt's lymphoma and alveolar rhabdomyosarcoma. T-LBL can be differentiated from B-LBL by its expression of T cell markers like CD1a, CD2, CD3, CD4, CD5, CD7 and CD8. The absence of Cyclin D1 distinguishes B-LBL from mantle cell lymphoma and the expression of TdT, CD34, CD43 and CD79a differentiates it from Ewing family tumours [7]. Burkitt lymphoma shows strong CD20, BCL6 expression and is negative for stem cell markers. Cytogenetic analysis may show 21q material as a recurring karyotypic abnormality. The standard treatment of B-LBL remains multiagent chemotherapy commonly used in ALL.

In a study conducted by Lin P et al., who analysed 25 cases with B-LBL, four patients (16%) were found to have soft tissue presentation [8]. All were males with age between ages 5 and 35. The tumours involved the infratemporal fossa, ankle, thoracic intercostal muscle, parotid and conjunctiva. Patients were treated

with combination chemotherapy regimens including H-CVAD alternating with methotrexate and cytarabine. Of 14 patients with available survival data, all achieved complete clinical response after combination chemotherapy. Nine patients remained in complete remission and were alive at the last follow-up. Galway N et al., described the case of a 11-year-old girl who was evaluated for soft tissue swellings adjacent to the lateral orbital wall [9]. She was diagnosed with B-LBL and started on systemic treatment based on the UKALL 2011 trial protocol. Chakra R et al., reported the case of a 56-year-old lady who presented with a uterine mass mimicking an endometrial sarcoma which was later diagnosed to be B-LBL [10].

## CONCLUSION(S)

The LBL presenting as a thigh mass is extremely rare and it should be managed with systemic chemotherapy similar to ALL. They have a similar prognosis compared to B-ALL and a better prognosis compared to T-LBL. Even though rare, LBL should be considered as a differential diagnosis in patients presenting with soft tissue swelling.

## REFERENCES

- [1] Bassan R, Maino E, Cortelazzo S. Lymphoblastic lymphoma: an updated review on biology, diagnosis, and treatment. *Eur J Haematol.* 2016;96(5):447-60.
- [2] Burkhardt B, Hermiston ML. Lymphoblastic lymphoma in children and adolescents: review of current challenges and future opportunities. *Br J Haematol.* 2019;185(6):1158-70.
- [3] Geethakumari PR, Hoffmann MS, Pemmaraju N, Hu S, Jorgensen JL, O'Brien S, et al. Extramedullary B lymphoblastic leukaemia/lymphoma (B-ALL/B-LBL): a diagnostic challenge. *Clin Lymphoma Myeloma Leuk.* 2014;14(4):e115-18.
- [4] Khurana S, Beltran M, Jiang L, Ayala E, Roy V. Primary cutaneous T-Cell lymphoblastic lymphoma: case report and literature review. *Case Rep Hematol.* 2019;2019:3540487.
- [5] Cortelazzo S, Ferreri A, Hoelzer D, Ponzoni M. Lymphoblastic lymphoma. *Crit Rev Oncol Hematol.* 2017;113:304-17.
- [6] Chen J, Tian X, Yu N, Peng L, Zhu H. T-Cell Lymphoblastic lymphoma with cutaneous involvement in a child: a rare case report. *Clin Cosmet Investig Dermatol.* 2022;15:2027-33.
- [7] Iwamuro M, Kawai Y, Yamawaki Y, Takata K, Yamamoto K. Precursor B lymphoblastic lymphoma involving the stomach. *Case Rep Gastrointest Med.* 2013;2013:930918. Doi: 10.1155/2013/930918.
- [8] Lin P, Jones D, Dorfman DM, Medeiros LJ. Precursor B-cell lymphoblastic lymphoma: a predominantly extranodal tumour with low propensity for leukaemic involvement. *Am J Surg Pathol.* 2000;24(11):1480-90.
- [9] Galway N, Johnston R, Cairns C, Thompson AJ. Precursor B cell lymphoblastic lymphoma presenting as periorbital swelling. *BMJ Case Rep.* 2016;2016:bcr2016215679.
- [10] Chakra RA, Najib B, Abdallah W, Akiki M, Khoury LE, Atoui A, et al. B-Cell lymphoblastic lymphoma in relapse presenting as a uterine mass: a case report and review of literature. *Case Rep Oncol.* 2021;14(2):868-73.

### PARTICULARS OF CONTRIBUTORS:

1. Senior Resident, Department of Medical Oncology, Regional Cancer Centre, Thiruvananthapuram, Kerala, India.
2. Assistant Professor, Department of Medical Oncology, Regional Cancer Centre, Thiruvananthapuram, Kerala, India.
3. Associate Professor, Department of Pathology, Regional Cancer Centre, Thiruvananthapuram, Kerala, India.

### NAME, ADDRESS, E-MAIL ID OF THE CORRESPONDING AUTHOR:

MT Sugeeth,  
Assistant Professor, Department of Medical Oncology, Regional Cancer Centre,  
Thiruvananthapuram, Kerala, India.  
E-mail: sugeethmt@gmail.com

### AUTHOR DECLARATION:

- Financial or Other Competing Interests: None
- Was informed consent obtained from the subjects involved in the study? Yes
- For any images presented appropriate consent has been obtained from the subjects. Yes

### PLAGIARISM CHECKING METHODS: [Jan H et al.]

- Plagiarism X-checker: Jan 09, 2023
- Manual Googling: Jan 31, 2023
- iThenticate Software: Feb 16, 2023 (14%)

### ETYMOLOGY: Author Origin

Date of Submission: **Jan 06, 2023**  
Date of Peer Review: **Jan 23, 2023**  
Date of Acceptance: **Feb 20, 2023**  
Date of Publishing: **May 01, 2023**