



Role of Ultrasonogram in Acute Abdomen in a Tertiary Hospital

Vaishnavi Venkat Pazhambalacode^{1*}, N. Paarthipan², G. Naveen Kumar² and C. R. Seena²

¹Saveetha Medical College and Hospital, Thandalam, Chennai, India.

²Department of Radiology, Saveetha Medical College and Hospital, Thandalam, Chennai, India.

Authors' contributions

This work was carried out in collaboration among all authors. All authors read and approved the final manuscript.

Article Information

DOI: 10.9734/JPRI/2021/v33i48A33247

Editor(s):

(1) Dr. Giuseppe Murdaca, University of Genoa, Italy.

Reviewers:

(1) M. Meer Chisthi, Govt Medical College, India.

(2) Mahesh Chandra, Govt. Medical College & Hospital, India.

Complete Peer review History: <https://www.sdiarticle4.com/review-history/75025>

Original Research Article

Received 02 August 2021

Accepted 09 October 2021

Published 06 November 2021

ABSTRACT

Introduction: Acute abdomen is a common presentation seen in the emergency department. Patients most commonly present with pain, which is a broad spectrum for assessment. Hence the clinician often needs an aid to come to a diagnosis. Ultrasonography is one of the leading imaging modality that helps to confirm the diagnosis made by the clinician.

Methodology: This was a retrospective study conducted in the Department of Radiology at Saveetha Medical College and Hospital between January 2021 to April 2021 with the objective to assess the efficacy of ultrasound in acute abdomen. Hundred patients who were admitted in the hospital with abdominal pain were chosen. Patients with the history of trauma, history of chronic abdominal pain and pregnant women were excluded from the study. Clinical history, physical examination, ultrasonogram, per-operative clinical findings and histopathological examination were used to come to the final conclusion.

Results: Out of hundred patients sixty-four (64%) were managed surgically. After obtaining histopathological results it was found that the sensitivity of ultrasound to diagnose a surgical condition was less compared to the histopathological investigation. The remaining thirty-six (36%) were managed medically after obtaining the diagnosis from ultrasound, lab investigations and

higher imaging modalities like magnetic resonance imaging(MRI) and computerized tomography(CT). The specificity of ultrasonogram was found to be really high while the sensitivity was less compared to other imaging modalities.

Conclusion: Ultrasonogram has established itself as a rapid,safe and cost effective imaging modality. It aids the clinician to come to a diagnosis or to confirm it leading to accurate treatment and patient survival.

Keywords: Acute abdomen; ultrasonogram; diagnosis.

1. INTRODUCTION

Ultrasonogram is an invaluable tool used in diagnosing because it is reliable,non-invasive, rapid, simple to perform and has no contraindications. It can be repeated as and when required without causing any adverse effect as no radiations are emitted thus making it a widely acceptable and used imaging modality.

Acute abdomen can be characterized as sudden onset of pain that may occur suddenly or gradually over a period of several hours which requires immediate diagnosis for early treatment either medically or surgically [1]. Thakur JK et al. [2] in their study mentioned that about 15% of all emergency hospitalization is due to acute abdominal pain as a result of infection,inflammation, vascular occlusion and obstruction.

Acute appendicitis, acute cholecystitis, cholelithiasis, renal calculi, intestinal obstruction are few common conditions encountered in the emergency department. Gynecological conditions like ovarian cyst,acute salpingitis are also of growing concern nowadays.

With too many differential diagnoses it becomes difficult for the clinician for which imaging modality can be used as a support to confirm or exclude diagnostic possibilities and to narrow down the differential diagnosis to give a prompt treatment.

2. MATERIALS AND METHODS

This was a retrospective study conducted at the Department of Radiology,Saveetha Medical College and Hospital for a period of 4 months from January 2021 to April 2021.The research consisted of hundred patients between the age of 17-80 years (fifty-one male and forty-nine female) who presented to the emergency department with the complaints of acute abdomen. They were admitted and provisional

diagnosis were made with the help of complete clinical history and physical examination. Simultaneously routine lab investigations and ultrasonogram was done to support the diagnosis.The equipment used was Philips affiniti 70 which uses a frequency of 50-60 Hz.

Out of the hundred patients thirty-six were managed conservatively and the rest sixty-four were operated at appropriate time. Operative findings were noted and fluid or tissue collected pre or per operatively were sent for histo-pathological examination. The histo-pathological report was noted. Final diagnosis was made after the surgery and histo-pathological report. For the remaining thirty-six patients cross-sectional imaging and lab parameters were considered to come to the final diagnosis. Comments on individual cases were noted. Ethical approval was obtained from Institutional Research Board.

3. RESULTS

According to the above results, ultrasound is highly specific but less sensitive for diagnosis of acute abdominal conditions.

4. DISCUSSION

In this study, out of hundred cases sixty-four cases (64%) were treated by surgery after making a provisional diagnosis. The correct diagnosis of the patients who underwent surgery was given after histopathological examination thus proving histopathology to be a gold standard investigation for surgical treatment. The ultrasonogram was found to have sensitivity of 71.42% and specificity of 100% for ovarian cyst.In case of cystitis sensitivity and specificity was 83.33% and 100% respectively. Obstructive Urolithiasis showed specificity 83.33% and sensitivity 100%, while pancreatitis showed 85.71% sensitivity and 96.49% specificity. Hepatic Mass was the only diagnosis to have 100% sensitivity and specificity.

Table 1. Sensitivity and specificity of ultrasonogram in diagnosing surgical condition

Ultrasonogram Diagnosis	No of cases	Correlation with Histopathology	Sensitivity	Specificity
Ovary Cyst	5	7	71.42%	100%
Torsion of ovary	2	3	66.66%	100%
Cholelithiasis	7	9	77.77%	100%
Calculus	2	3	66.66%	100%
Cholecystitis				
Choledocholithiasis	5	6	83.33%	100%
Llver Abscess	3	4	75%	100%
Pyelonephritis	3	5	60%	100%
Hepatic Mass	4	4	100%	100%
Renal Mass	2	3	66.66%	96.72%
Obstructive Urolithiasis	10	12	83.33%	94.23%
Cystitis	5	6	83.33%	100%
Acute Appendicitis	7	9	77.77%	92.72%
Pancreatitis	6	7	85.71%	96.49%
Testicular Torsion	3	4	75%	100%

Table 2. Sensitivity and specificity of ultrasonogram in diagnosing medical condition

Ultrasonogram Diagnosis	No of cases	Correlation with Higher Modality	Sensitivity	Specificity
Renal Calculi	16	18	88.88%	77.77%
Cirrhosis	8	10	80%	100%
Ascites	2	3	66.66%	100%
Hepatic steatosis(Fatty Liver)	6	8	75%	89.28%
Benign Prostate Hypertrophy	4	5	80%	100%

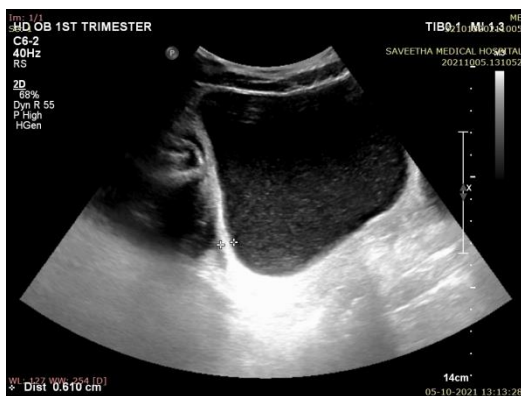

Fig. 1. USG Abdomen showing cystitis with diffuse wall thickening more than 2mm and echogenic freely mobile intraluminal debris

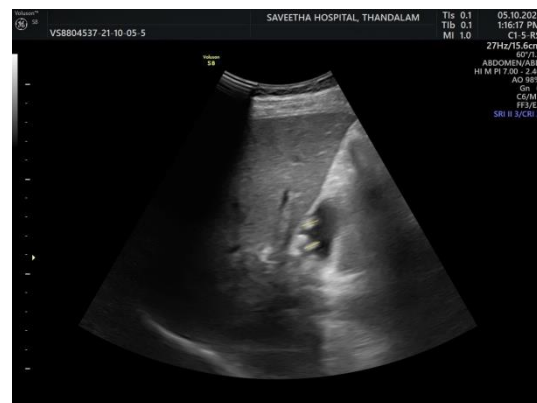

Fig. 2. USG Abdomen showing gallstone of size 3*4 mm

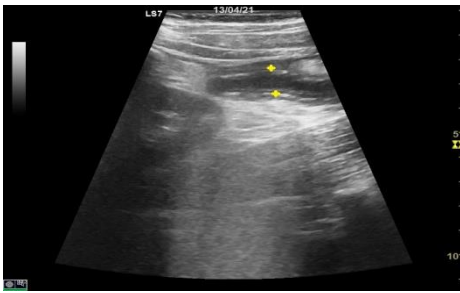


Fig. 3. USG Abdomen showing thick walled appendix

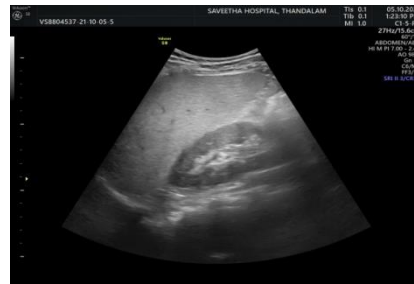

Fig. 4. USG Abdomen showing hepatic steatosis (fatty liver)

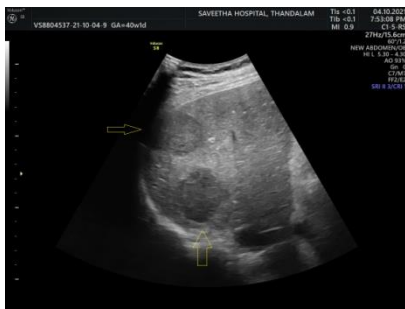

Fig. 5. USG Abdomen showing liver mass

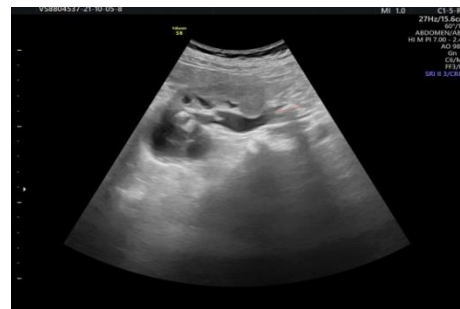

Fig. 6. USG Abdomen showing renal calculi of size 3*5 mm

Acute appendicitis showed sensitivity of 77.77% and specificity of 92.72%. Ultrasound diagnosis of acute appendicitis in one patient turned out to be Meckel's diverticulum after surgical procedure and histopathological examination.

Similarly two cases of pancreatitis and one case of small neuroendocrine tumour of pancreas were missed on ultrasound due to poor acoustic window secondary to excessive bowel gas artifact.

As the above results show the accuracy of ultrasound in gynecological conditions, similarly McGrath et al. [3] in their study on the role of early USG in the management of the acute abdomen concluded that it is most useful in the diagnosis of gynecological disorders.

Mishra et al. [4] in their study of imaging for acute abdomen had 13 cases of appendicitis. USG was diagnostic in 11 with sensitivity and specificity of 91.6% and 97%. Zoller et al. [4] in their meta analysis demonstrated that USG has sensitivity of 85% and a specificity of 96% in diagnosing acute appendicitis. There are a few studies which have looked at the various parameters we analyzed. Al Ajerami [5] in his study on acute appendicitis found the overall sensitivity and specificity of ultrasound, using surgical outcome as the gold standard, to be 84.8% and 83.3%

respectively. Allemann et al. [6] reported that in USG done by surgeons for patients with acute abdominal pain the correct diagnostic rate went from 348 patients (70%) to 414 patients (83%).

There were a total of nine cases of cholelithiasis where patients presented with tenderness in the right upper quadrant. Only seven of them were picked up by ultrasound and the rest two were identified post operatively. Thus the sensitivity of diagnosis in ultrasound was 77.77%. Ralls PW, et al. [7] found that the positive predictive value for GB calculi combined with positive sonographic Murphy's sign was 92.2% and when along with GB wall thickening, it was 95.2%.

Out of eighteen cases of renal calculi sixteen were diagnosed correctly by ultrasound. The rest two were identified by KUB X-ray, thus showing a sensitivity of ultrasound for identifying renal calculi as 77.77%. Also one case of simple renal cyst turned out to be renal cell carcinoma [8].

Hepatic steatosis (fatty liver) was found to have sensitivity of 75% and specificity of 89.28%. We missed a case of hemangioma in the background of hepatic steatosis in ultrasound which was correctly identified by computerized tomography (CT scan) thus showing that higher modalities of investigations are required for diagnosing medical conditions.

From the above results it can be seen that ultrasound can be used for making diagnosis in the majority of the systems. Gold standard investigations was dependent on the provisional diagnosis made. If the diagnosis made required surgical intervention then histopathology was considered investigation of choice. In case of medical diagnosis cross sectional imaging like magnetic resonance imaging (MRI) and computerized tomography (CT) was considered gold standard supported by lab parameters.

5. CONCLUSION

Ultrasonography is a reliable radiological modality that is cheap, non-invasive, rapid and easily operable. It can be used by the clinician to find the extent of the disease or for definitive diagnosis. They have no contraindications or any adverse effects like other imaging modalities as result they can be repeated as and when required thus giving the clinician more chance of getting the accurate diagnosis.

DISCLAIMER

The products used for this research are commonly and predominantly use products in our area of research and country. There is absolutely no conflict of interest between the authors and producers of the products because we do not intend to use these products as an avenue for any litigation but for the advancement of knowledge. Also, the research was not funded by the producing company rather it was funded by personal efforts of the authors.

CONSENT

As per international standard or university standard, patients' written consent has been collected and preserved by the author(s).

ETHICAL APPROVAL

As per international standard or university standard written ethical approval has been collected and preserved by the author(s).

ACKNOWLEDGEMENT

We thank the Department of Radiology for providing us with data for this study.

COMPETING INTERESTS

Authors have declared that no competing interests exist.

REFERENCES

1. Das S. Examination of acute abdomen. A manual of clinical surgery Ch. 2000;33:335-356.
2. Thakur JK, Kumar R, et al. Epidemiology of acute abdominal pain: A cross-sectional study in a tertiary care hospital of Eastern India. *Int Surg J.* 2019;6(2):345-348
3. McGrath FP, Keeling F. The role of early sonography in the management of the acute abdomen *Clin Radiol.* 1991;44(3):172-4.
4. Zoller WG, Kellner H, Schwerek WB. Value of ultrasound in diagnosis of acute appendicitis. *Bildgebung.* 1996;63(2):78-82.
5. Al-Ajerami Y. Sensitivity and specificity of ultrasound in the diagnosis of acute appendicitis. *East Mediterr Health J.* 2012;18(1):66-9.
6. Allemann F, Cassina P, Rothlin M, Largiader F. Ultrasound scans done by surgeons for patients with acute abdominal pain. *Eur J Surg.* 1999;165(10):966-70.
7. Ralls PW, Colletti PM, Lapin SA, et al. Real-time sonography in suspected acute cholecystitis. Prospective evaluation of primary and secondary signs. *Radiology.* 1985;155(3):767-71.
8. Mishra DS, Magu S, Sharma N, Rattan KN, Tiwari AD, Rohilla S. Imaging in acute abdomen. *Indian J Pediatr.* 2003;70(1):15-9.