



A Retrospective Study on Identification of Anterior Loop Pattern of Mental Nerve Entry into Mental Foramen in Digital Orthopantomography among South Indian Population

M. Srithika^a and Lavanya Prathap^{a*}

^a Saveetha Dental College and Hospital, Saveetha Institute of Medical and Technical Sciences, Saveetha University, Chennai-600077, India.

Authors' contributions

This work was carried out in collaboration between both authors. Both authors read and approved the final manuscript.

Article Information

DOI: 10.9734/JPRI/2021/v33i60B35010

Open Peer Review History:

This journal follows the Advanced Open Peer Review policy. Identity of the Reviewers, Editor(s) and additional Reviewers, peer review comments, different versions of the manuscript, comments of the editors, etc are available here: <https://www.sdiarticle5.com/review-history/78952>

Original Research Article

Received 21 October 2021
Accepted 26 December 2021
Published 27 December 2021

ABSTRACT

Background: In the premolar location of mandible, the mental nerve's entry into the mental foramen pattern is a significant landmark. Different patterns of mental nerve entrance have been discovered. The current experiment was attempted to detect the different entry routes of the mental nerve into the mandible using panoramic radiographs, which are employed in pre-surgical evaluation.

Materials and Methods: The current study used a total of 200 panoramic radiographs collected for diagnostic purposes. The location and entrance pattern of the mental nerve on the both sides were noted on the radiographs. Straight, looping, and perpendicular entry patterns were identified in the data. The data is tabulated and statistically analysed in SPSS software using Chi-square.

Results: The existence of an anterior loop was determined to be the most usual pattern of entry of the mental nerve, accounting for 79 percent of the total radiographs examined 21 percent, and a perpendicular pattern 6 percent. The p value is 0.432 and p value 0.309, with respect to age and gender respectively which is statistically not significant.

Conclusion: The findings obtained from the study within the limits, it can be stated that the straight

*Corresponding author: E-mail: lavanyap.sdc@saveetha.com, lavanya.anatomist@gmail.com;

pattern of anterior loop of mental nerve was the most common. A panoramic radiograph may be a viable radiological tool for detecting the existence of an anterior loop that should be confirmed in order to plan surgical treatments in the mandibular premolar region prior to surgery.

Keywords: Anterior loop pattern; panoramic radiography; emerging patterns; inventive technique; mental nerve.

1. INTRODUCTION

The inferior alveolar nerve is a mandibular nerve branch that starts on the lingual side of the mandibular ramus and passes down to the mandibular canal, feeding teeth of mandible and adjoining gums [1]. One of the terminal branches of the inferior alveolar nerve is the mental nerve, which arises from the mental foramen and supplies the skin and mucous membrane of the buccal vestibule from the medial border of the masseter muscle to the midline [2].

Before the nerve emerges from the mental foramen, some authors documented an anterior loop [3]. The structure "where the inferior and anterior to the mental foramen has been crossed by mental neurovascular bundle then it doubles or loops back to exit the mental foramen" was first described by Bavitz and Misch. In around 11-60% of panoramic radiographs, this can be seen. More about the additional routes of the mental nerve as it escapes via the mental foramen has not been described. Some investigations classified the pattern as looped or non-looped, or defined it as posteriorly directed, anteriorly directed, or both [4]. The experience from our previous studies [5-14] have led us to focus on the current topic.

The most common problem during implant placement in the mandibular premolar region is neurosensory changes in the chin and lower lip. Complications can emerge when crucial critical structures like the mental foramen and anterior mental loop are not appropriately recognised and safeguarded [15]. Using proper radiography techniques, the exact location of the anatomical structures should be established prior to surgery to avoid harm to these essential structures [15,16]. Although a number of morphometric investigations have shown the mental nerve's entry pattern into the mental foramen, only a few radiography studies have been conducted in this regard [17]. To plan these surgical procedures, anatomic landmarks are commonly discovered utilising panoramic radiography.

The purpose of this study is to see if a OPG is enough to detect the appearance of an anterior

loop pattern and other related variable patterns of mental nerve entrance, or if more advanced imaging techniques are required. Our research team has published high-quality papers in the past [18–37]. The goal of this study is to use digital orthopantomography to discover the anterior loop pattern of the mental nerve's entry into the mental foramen.

2. MATERIALS AND METHODS

This is a retrospective study conducted in a private dental college hospital in chennai and the study was approved by the institutional reveal board. Total 200 panoramic radiographs obtained from records maintained in the Department of Oral Medicine and Radiology were randomly selected for the study. Only high-quality radiographs with respect to geometric accuracy and contrast of image were selected for the study. Radiographs showing radiolucent or radiopaque lesions in the mental foramen region of mandible and evidence of fracture around the mental foramen and mandibular canal region, radiographs showing supernumerary or unerupted teeth in the mental foramen region and radiographs showing processing or exposure errors and artifacts obscuring visibility of structures in the mandible were excluded from the study. The radiographs were evaluated for the pattern of entry of the mental nerve into the mental foramen on either side of the mandible. The observations thus made were recorded as Anterior loop (AL), straight (S), or Perpendicular (P) and the total numbers of patterns observed on both sides were recorded. Inter-observer variability was assessed using the kappa test. Tabulations for the presence of each pattern were done for both sides and the percentages calculated and analyzed using the SPSS tool.

3. RESULTS

The most common pattern of mental nerve entry was found to be straight, accounting for seventy nine percent of all samples examined. The straight patterns is followed by the existence of an anterior loop (21%), and a perpendicular type of pattern. (6 percent). The p value is 0.432 and

p value 0.309, with respect to age and gender respectively which is statistically not significant. (Figs 1,2).

4. DISCUSSION

Maximum samples account's for straight type of entrance of mental nerves into mental foramen, according to the findings of this study.

Few investigations in cadaveric mandibles have looked at the transitional section of the nerve, between the mandibular canal and the mental foramen is the inferior alveolar nerve. Solar and colleagues categorized their examples into loop and non-loop kinds [38]. The author looked at the real course of the mental nerve's emergence and classified it as with various patterns. An investigation of the origins of the mental nerve in a varied populations. A straight pattern of the mental canal entering into the mental foramen directly was discovered [39].

So yet, no radiographic tests have been conducted to see if such patterns are detectable on radiographs. Despite the fact that radiographic studies have not reported the numerous forms of the mental nerve's entrance into the mental foramen. Dissimilar diagnostic techniques, equipment, and poor radiography

quality may explain the diversity in the radiographic assessment of the anterior loop when reported for the varied rule used to describe the anterior loop. The inability to tell it apart from normal trabecular patterns is the most probable explanation [40]. The appearance of the anterior loop pattern on three-dimensional cone beam tomography has been determined to be significantly better in studies [41].

The MF was nearer to the alveolar crest in the imaging with an anterior loop than in the radiographs with no loop, according to the current study. As a result of this discovery, It's possible that the mental nerve must loop back to enter the foramen when the mental foramen is little higher in the vertical planar line.

Finally, because of the existence of the anterior loop, the morphology of the premolar region of mandible has clinical relevance in preliminary assessment of surgical treatments. Neurosensory changes in the chin and lower lip may result from damage to this nerve bundle. The implantation of endosseous implants in the anterior inter-foraminal area has piqued researchers' curiosity. The most posterior implant should be positioned as near to the mental foramen as possible to maximise the space between implants [42].

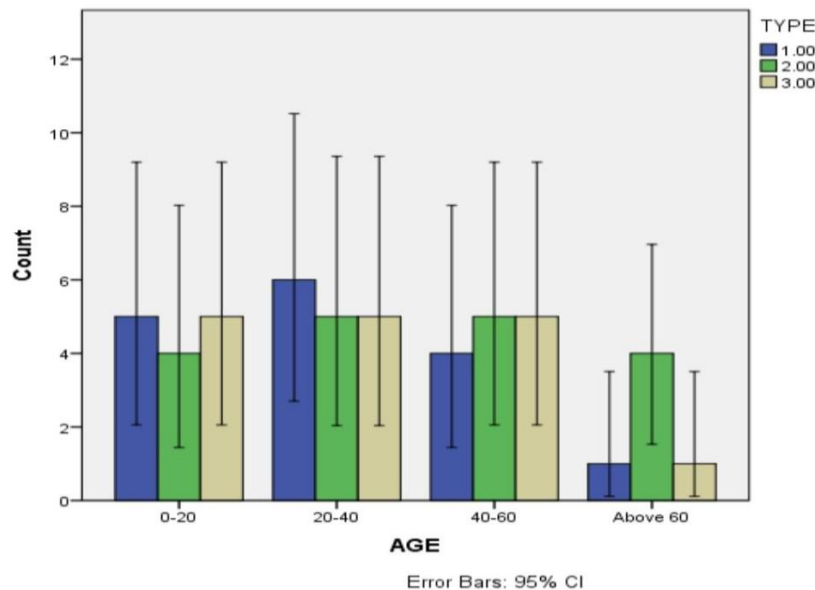


Fig. 1. The frequency distribution with respect to age. The X axis presents the age and the y axis presents the number of samples. Type I is anterior loop (blue), type II is straight (green), type III is perpendicular (yellow). Anterior loop pattern is observed in more frequency among age group 20-40 yrs. The Chi square test was observed with p value 0.432, which is not significant

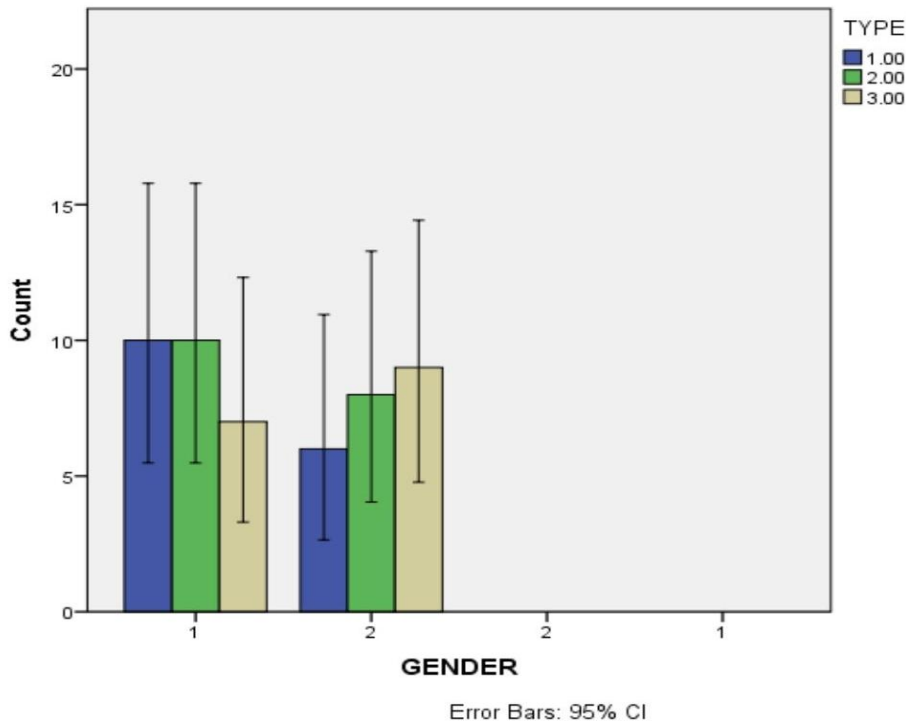


Fig. 2. The frequency distribution with respect to gender. In the X axis, 1 presents male and 2 represents female. In the y axis the numbers represent the number of samples. Type I is anterior (blue), type II is straight (green), type III is perpendicular (yellow), among which anterior loop and straight pattern are more in males than females. Chi square test was done with p value 0.309, which is statistically not significant

The distal aspect of an implant in the mental region should be 1mm anterior to the anterior edge of the mental foramen, according to Bavitz et al. [43] However, some writers suggest that the MF and the most dorsal implant be separated by at least 6 mm. However, the study can be expanded to a larger scale in the future.

5. CONCLUSION

The findings obtained from the study within the limits, it can be stated that the straight pattern of anterior loop of mental nerve was the most common. A panoramic radiograph may be a viable imaging tool for detecting the existence of an anterior loop that needs to be confirmed in order to plan surgical treatments in the premolar region of mandible prior to surgery. The exact design of premolar region of mandible, which is crucial for planning any surgical operations in this region, may need studies involving a range of ethnic groups.

CONSENT

It is not applicable.

ETHICAL APPROVAL

As per international standard or university standard written ethical approval has been collected and preserved by the author(s).

ACKNOWLEDGEMENT

We thank Saveetha Dental College and Hospitals for the successful completion of the study.

COMPETING INTERESTS

Authors have declared that no competing interests exist.

REFERENCES

1. Kieser J, Kuzmanovic D, Payne A, Dennison J, Herbison P. Patterns of emergence of the human mental nerve [Internet]. Archives of Oral Biology. 2002; 47:743–7. Available: [http://dx.doi.org/10.1016/s0003-9969\(02\)00067-5](http://dx.doi.org/10.1016/s0003-9969(02)00067-5)

2. Arzouman MJ, Otis L, Kipnis V, Levine D. Observations of the anterior loop of the inferior alveolar canal. *Int J Oral Maxillofac Implants*. 1993;8(3):295–300.
3. Bavitz JB, Harn SD, Hansen CA, Lang M. An anatomical study of mental neurovascular bundle-implant relationships. *Int J Oral Maxillofac Implants*. 1993;8(5):563–7.
4. Ngeow WC, Dionysius DD, Ishak H, Nambiar P. Effect of ageing towards location and visibility of mental foramen on panoramic radiographs. *Singapore Dent J*. 2010;31(1):15–9.
5. Shruthi M, Preetha S. Effect of Simple Tongue Exercises in Habitual Snorers [Internet]. *Research Journal of Pharmacy and Technology*. 2018;11:3614. Available:<http://dx.doi.org/10.5958/0974-360x.2018.00665.0>
6. Preetha S, Packyanathan J. Comparison of the effect of Yoga, Zumba and Aerobics in controlling blood pressure in the Indian population [Internet]. *Journal of Family Medicine and Primary Care*. 2020;9:547. Available:http://dx.doi.org/10.4103/jfmpc.jfmpc_607_19
7. J SK, Saveetha Dental College and Hospitals, Road PH, Chennai, Tamilnadu, Preetha S, et al. Effect of aerobics exercise and yoga on blood pressure in hypertensives [Internet]. *International Journal of Current Advanced Research*. 2017;6:3124–6. Available:<http://dx.doi.org/10.24327/ijcar.2017.3126.0200>
8. Prathap L, Suganthirababu P, Ganesan D. Fluctuating Asymmetry of Dermatoglyphics and DNA Polymorphism in Breast Cancer Population [Internet]. *Indian Journal of Public Health Research & Development*. 2019;10:3574. Available:<http://dx.doi.org/10.5958/0976-5506.2019.04141.x>
9. Lavanya J, Prathap S, Alagesan J. Digital and palmar dermal ridge patterns in population with breast carcinoma. *Biomedicine*. 2014;34(3):315–21.
10. Prathap L, Jagadeesan V. Association of quantitative and qualitative dermatoglyphic variable and DNA polymorphism in female breast cancer population. *Online J Health* [Internet]; 2017. Available:[https://www.researchgate.net/profile/Prathap_Suganthirababu/publication/321606278_Association_of_Quantitative_and_Qualitative_Dermatoglyphic_Variable_and](https://www.researchgate.net/profile/Prathap_Suganthirababu/publication/321606278_Association_of_Quantitative_and_Qualitative_Dermatoglyphic_Variable_and_DNA_Polymorphism_in_Female_Breast_Cancer_Population/links/5a28c8f1a6fdcc8e8671c0cd/Association-of-Quantitative-and-Qualitative-Dermatoglyphic-Variable-and-DNA-Polymorphism-in-Female-Breast-Cancer-Population.pdf)
11. Lavanya J, Kumar VJ, Sudhakar N, Prathap S. Analysis of DNA repair genetic polymorphism in breast cancer population. *Int J Pharma Bio Sci* [Internet]; 2015. Available:https://scholar.google.ca/scholar?cluster=8949053652564257518&hl=en&as_sdt=0,5&scioldt=0,5
12. Prathap L, Suganthirababu P. Estrogen Exposure and its Influence in DNA Repair Genetic Variants in Breast Cancer Population [Internet]. *Biomedical and Pharmacology Journal*. 2020;13:1321–7. Available:<http://dx.doi.org/10.13005/bpj/2001>
13. Ravikumar H, Prathap L, Preetha S. Analysis of Palmar Atd Angle in Population with Malocclusion. 2020;1174–82.
14. Prathap L. Interplay of Oxidative Stress and Lipoproteins in Breast Carcinoma Initiation, Promotion and Progression -A Systematic Review. *Pal Arch's Journal of Archaeology of Egypt/ Egyptology* [Internet]. 2021 Jan 7 [cited 2021 Mar 9];17(7). Available: <http://dx.doi.org/>
15. Ulm CW, Solar P, Blahout R, Matejka M, Watzek G, Watzek G, et al. Location of the mandibular canal within the atrophic mandible [Internet]. *British Journal of Oral and Maxillofacial Surgery*. 1993;31:370–5. Available:[http://dx.doi.org/10.1016/0266-4356\(93\)90193-z](http://dx.doi.org/10.1016/0266-4356(93)90193-z)
16. Hu KS, Yun HS, Hur MS, Kwon HJ, Abe S, Kim HJ. Branching patterns and intraosseous course of the mental nerve. *J Oral Maxillofac Surg*. 2007;65(11):2288–94.
17. Juodzbalys G, Wang HL, Sabalys G. Anatomy of mandibular vital structures. Part I: mandibular canal and inferior alveolar neurovascular bundle in relation with dental implantology. *J Oral Maxillofac Res*. 2010;1(1):e2.
18. Sekar D, Lakshmanan G, Mani P, Biruntha M. Methylation-dependent circulating microRNA 510 in preeclampsia patients. *Hypertens Res*. 2019;42(10):1647–8.
19. Princeton B, Santhakumar P, Prathap L. Awareness on Preventive Measures taken by Health Care Professionals Attending COVID-19 Patients among Dental

- Students. *Eur J Dent.* 2020;14(S 01): S105–9.
20. Logeshwari R, Rama Parvathy L. Generating logistic chaotic sequence using geometric pattern to decompose and recombine the pixel values. *Multimed Tools Appl.* 2020;79(31-32):22375–88.
 21. Johnson J, Lakshmanan G, M B, RMV, Kalimuthu K, Sekar D. Computational identification of MiRNA-7110 from pulmonary arterial hypertension (PAH) ESTs: a new microRNA that links diabetes and PAH. *Hypertens Res.* 2020;43(4):360–2.
 22. Paramasivam A, Priyadharsini JV, Raghunandhakumar S, Elumalai P. A novel COVID-19 and its effects on cardiovascular disease. *Hypertens Res.* 2020;43(7):729–30.
 23. Pujari GRS, Subramanian V, Rao SR. Effects of *Celastrus paniculatus* Willd. and *Sida cordifolia* Linn. in Kainic Acid Induced Hippocampus Damage in Rats. *Ind J Pharm Educ.* 2019;53(3):537–44.
 24. Rajkumar KV, Lakshmanan G, Sekar D. Identification of miR-802-5p and its involvement in type 2 diabetes mellitus. *World J Diabetes.* 2020;11(12):567–71.
 25. Ravisankar R, Jayaprakash P, Eswaran P, Mohanraj K, Vinitha G, Pichumani M. Synthesis, growth, optical and third-order nonlinear optical properties of glycine sodium nitrate single crystal for photonic device applications. *J Mater Sci: Mater Electron.* 2020;31(20):17320–31.
 26. Wu S, Rajeshkumar S, Madasamy M, Mahendran V. Green synthesis of copper nanoparticles using *Cissus vitiginea* and its antioxidant and antibacterial activity against urinary tract infection pathogens. *Artif Cells Nanomed Biotechnol.* 2020;48(1):1153–8.
 27. Vikneshan M, Saravanakumar R, Mangaiyarkarasi R, Rajeshkumar S, Samuel SR, Suganya M, et al. Algal biomass as a source for novel oral nano-antimicrobial agent. *Saudi J Biol Sci.* 2020;27(12):3753–8.
 28. Alharbi KS, Fuloria NK, Fuloria S, Rahman SB, Al-Malki WH, Javed Shaikh MA, et al. Nuclear factor-kappa B and its role in inflammatory lung disease. *Chem Biol Interact.* 2021;345:109568.
 29. Rao SK, Kalai Priya A, Manjunath Kamath S, Karthick P, Renganathan B, Anuraj S, et al. Unequivocal evidence of enhanced room temperature sensing properties of clad modified Nd doped mullite Bi₂Fe₄O₉ in fiber optic gas sensor [Internet]. *Journal of Alloys and Compounds.* 2020;838: 155603. Available: <http://dx.doi.org/10.1016/j.jallcom.2020.155603>
 30. Bhavikatti SK, Karobari MI, Zainuddin SLA, Marya A, Nadaf SJ, Sawant VJ, et al. Investigating the Antioxidant and Cytocompatibility of *Mimusops elengi* Linn Extract over Human Gingival Fibroblast Cells. *Int J Environ Res Public Health* [Internet]. 2021;18(13). Available: <http://dx.doi.org/10.3390/ijerph18137162>
 31. Marya A, Karobari MI, Selvaraj S, Adil AH, Assiry AA, Rabaan AA, et al. Risk Perception of SARS-CoV-2 Infection and Implementation of Various Protective Measures by Dentists Across Various Countries. *Int J Environ Res Public Health* [Internet]. 2021;18(11). Available: <http://dx.doi.org/10.3390/ijerph18115848>
 32. Barma MD, Muthupandiyani I, Samuel SR, Amaechi BT. Inhibition of *Streptococcus mutans*, antioxidant property and cytotoxicity of novel nano-zinc oxide varnish. *Arch Oral Biol.* 2021;126:105132.
 33. Vijayashree Priyadharsini J. In silico validation of the non-antibiotic drugs acetaminophen and ibuprofen as antibacterial agents against red complex pathogens. *J Periodontol.* 2019;90(12): 1441–8.
 34. Priyadharsini JV, Vijayashree Priyadharsini J, Smiline Girija AS, Paramasivam A. In silico analysis of virulence genes in an emerging dental pathogen *A. baumannii* and related species [Internet]. *Archives of Oral Biology.* 2018;94:93–8. Available: <http://dx.doi.org/10.1016/j.archor.2018.07.001>
 35. Uma Maheswari TN, Nivedhitha MS, Ramani P. Expression profile of salivary micro RNA-21 and 31 in oral potentially malignant disorders. *Braz Oral Res.* 2020;34:e002.
 36. Gudipani RK, Alam MK, Patil SR, Karobari MI. Measurement of the Maximum Occlusal Bite Force and its Relation to the Caries Spectrum of First Permanent Molars in Early Permanent Dentition. *J Clin Pediatr Dent.* 2020;44(6): 423–8.
 37. Chaturvedula BB, Muthukrishnan A, Bhuvaraghan A, Sandler J,

- Thiruvengkatachari B. Dens invaginatus: a review and orthodontic implications. Br Dent J. 2021;230(6):345–50.
38. Rosenquist B. Fixture placement posterior to the mental foramen with transpositioning of the inferior alveolar nerve. Int J Oral Maxillofac Implants. 1992 Spring;7(1):45–50.
39. Mardinger O, Chaushu G, Arensburg B, Taicher S, Kaffe I. Anterior loop of the mental canal: an anatomical-radiologic study. Implant Dent. 2000;9(2):120–5.
40. Yosue T, Brooks SL. The appearance of mental foramina on panoramic radiographs. I. Evaluation of patients [Internet]. Oral Surgery, Oral Medicine, Oral Pathology. 1989;68:360–4.
Available:[http://dx.doi.org/10.1016/0030-4220\(89\)90224-7](http://dx.doi.org/10.1016/0030-4220(89)90224-7)
41. Chau A. Comparison between the use of magnetic resonance imaging and conebeam computed tomography for mandibular nerve identification [Internet]. Clinical Oral Implants Research. 2012;23: 253–6.
Available: <http://dx.doi.org/10.1111/j.1600-0501.2011.02188.x>
42. Von Arx T, Lozanoff S. Clinical Oral Anatomy: A Comprehensive Review for Dental Practitioners and Researchers. Springer. 2016;561.
43. Jacobs R, Mraiwa N, Van Steenberghe D, Gijbels F, Quiryne M. Appearance, location, course, and morphology of the mandibular incisive canal: an assessment on spiral CT scan [Internet]. Dentomaxillofacial Radiology. 2002;31: 322–7.
Available:<http://dx.doi.org/10.1038/sj.dmf.4600719>

© 2021 Srithika and Prathap; This is an Open Access article distributed under the terms of the Creative Commons Attribution License (<http://creativecommons.org/licenses/by/4.0>), which permits unrestricted use, distribution, and reproduction in any medium, provided the original work is properly cited.

Peer-review history:
The peer review history for this paper can be accessed here:
<https://www.sdiarticle5.com/review-history/78952>