



Effect of Combination Therapy of *Garcinia kola* Seed and Vitamin E in Acetaminophen Induced Hepatotoxicity and Oxidative Stress in Albino Rats

H. A. Waribo^{1*}, E. S. Bartimaeus¹, N. Nduka¹ and H. U. Nwanjo²

¹Department of Medical Laboratory Science, Rivers State University, Nkpolu Oroworukwu, Port Harcourt, Rivers State, Nigeria.

²Department of Medical Laboratory Science, Imo State University, Owerri, Nigeria.

Authors' contributions

This work was carried out in collaboration among all authors. Author HAW designed the study, managed the literature searches and wrote the first draft of the manuscript, managed sample collections and analyses of the study. Author ESB performed the statistical analysis. Authors NN and HUN edited the literature reviews and supervised the work. All authors read and approved the final manuscript.

Article Information

DOI: 10.9734/IJBCRR/2019/v27i430127

Editor(s):

(1) Prof. Halit Demir, Department of Chemistry, Faculty of Art and Science, Yuzuncu, Yil University, Turkey.

Reviewers:

(1) Ioana Stanciu, University of Bucharest, Romania.

(2) Evelyn Sharon Sukumaran, SRM College of Pharmacy, India.

Complete Peer review History: <http://www.sdiarticle4.com/review-history/51592>

Original Research Article

Received 10 July 2019
Accepted 17 September 2019
Published 03 October 2019

ABSTRACT

Acetaminophen, used for antipyretic and analgesic purposes has been known to exhibit toxic effects on the organs because of its ability to generate free radicals, causing varieties of diseases. This study investigated the impact of the combined formed of *Garcinia kola* seed and Vitamin E pretreatment exposure on hepatotoxicity and oxidative stress induced by acetaminophen in Albino Rats. Five groups of animals were used for this study. Group 1 as the control received distilled water orally only, group 2 as toxicity control intoxicated with 800 mg acetaminophen intraperitoneally. The other three groups were pretreated with various doses of either *Garcinia kola* seed extract or vitamin E or a combined form respectively by oral gavage method for 7 days before induction with acetaminophen intraperitoneally on the 8th day and sacrificed under chloroform anaesthesia. Acetaminophen induction significantly rise ($p < 0.05$) the hepatic enzyme levels (ALT, AST, and ALP) and a marked reduction of the antioxidant enzymes (SOD, CAT and GPX) in group 2 animals when compared with the control. There was also a significant rise ($p < 0.05$) in the MDA

*Corresponding author: E-mail: helywary@yahoo.com;

levels. Meanwhile the combined form of *Garcinia kola* seed extract and Vitamin E pretreatment exposure on the organs showed no synergetic ameliorative potentials as compared with the single pretreatment exposure with *Garcinia kola* and Vitamin E respectively. The morphology of the tissue cells pretreated with these combined formed exhibited features showing signs of cell damages and slow recovery from the toxicity. Therefore combining *Garcinia kola* and Vitamin E may lost its ameliorative and protective effect as seen in this induced acetaminophen albino rats implying that *Garcinia kola* seed and Vitamin E should not be taken in a combined form.

Keywords: *Garcinia kola*; Vitamin E; acetaminophen; toxicity; albino rat.

1. INTRODUCTION

Garcinia kola plant is one amongst these medicinal plants common in this region. It is available, cheap and chewed by many in this region which prompted its choice in this study. *Garcinia kola* is a member of the family *Clusiaceae guttiferæ*. Phytochemical studies show that *Garcinia kola* contains phenolic compounds, steroids, xanthenes and benzophenones [1] of which the biflavonoids are the most active component of the plant as stated by Adegboye [2].

In line with this protective effect, α -tocopherol, the most biological active form of vitamin E is employed as an antioxidant in the glutathione peroxidase pathway. It salvages the body tissue from damage caused by free radicals. α -tocopherol reacts with free radicals generated from the lipid peroxidation thereby protecting the cell membranes from oxidation [3].

Liver is the most versatile complex internal organ of mammalian body that plays a vital role in metabolism of foreign compounds, synthesis of macromolecules, homeostasis of internal environment and conversion of endogenous and exogenous chemical to harmless compounds that are easily removed from the system [4].

Exposure to the free radicals derived from environmental toxicants, chemicals and drugs cause liver injury [5]. These free radicals induced lipid peroxidation which is believed to be one of the major causes of cell membrane damage leading to a number of pathological situations.

Acetaminophen is one of the drugs that causes drug induced liver injury which might cause death in Western and developing countries. It is safe at therapeutic dose but causes liver failure in over dose [6]. It is readily available without prescription, used for antipyretic and analgesic purposes [7]. It is linked to hepato toxicity because of the ability to generate free radicals

which might subsequently result to variety of liver diseases and disorders [8].

The liver metabolizes certain drugs by using cytochrome P450 pathway, resulting in the generation of N-acetyl-p-benzoquinoneimine (NAPQI), a highly toxic reactive intermediate that is readily detoxified by conjugation with glutathione (GSH) under normal conditions [9], but if this detoxification does not take place, these metabolites then start to affect the cells ensuring liver damage. Sustained over dose of acetaminophen enhances the buildup of N-acetyl-p-benzoquinoneimine (NAPQI) which covalently binds to cellular macro molecules resulting in acute hepatic necrosis [10]. Oxidative stress is usually occasioned by the increased level of this highly reactive species, NAPQI via lipid peroxidation causing hepatotoxicity [11]. Accumulation of the reactive oxygen species (ROS), a byproduct of cellular metabolism in the system gives room to oxidative stress [12].

Garcinia kola seed and Vitamin E are known to be hepato- protective as a result of their phytochemical and anti-oxidant properties respectively. Hence the attempt to investigate the impact of the combined form of both against acetaminophen induced hepatotoxicity and oxidative stress following acute pretreatment exposure.

2. MATERIALS AND METHODS

2.1 *Garcinia kola* Paste Preparation

The seeds of *Garcinia kola* were purchased from Mile 1 Market, Diobu, in Port Harcourt in Rivers State. They were sorted to remove any contaminants, dead matter, sand particles and then air dried for some days. Two (2) kg, of *Garcinia kola* nuts were oven dried at 45°C and ground using a grinding machine. The pulverized powder was macerated in a maceration jar with distilled water for twenty four hours. During the period of maceration, it was well shaken three

times before filtration. The Whatman No.1 filter paper was folded into four parts and placed in the funnel with the beaker under the funnel, and then the content was carefully poured into the funnel which gradually filtered through the paper into the beaker. The filtration process was repeated for about 2-3 times to have a clear filtrate. After obtaining a clear filtrate, it was then transferred into a clean evaporating dish and heated on a steam bath at 45°C. The water gradually evaporated out leaving the extract in a brownish paste like form.

2.2 Experimental Animals

A total number of 15 Rats made up of both male and females with an average weight of 80-120 g were procured and used to determine the LD₅₀ of the aqueous *Garcinia kola* extract following acute toxicity exposure as reported by [13,14]. Forty (40) Albino Rats were used for the sub chronic testing. The animals were kept in a well ventilated cage with 12 hours natural light/dark cycle. They were divided into groups and allowed to acclimatize for 2 weeks to enable them get used to the handling process during the research process. They were fed with commercially prepared Rat feed (finisher) which was purchased from the Top feed Company, Eastern Premier Feed Mill Ltd, Aba, Abia State, Nigeria and had access to water (ad libitum) throughout the period. The conditions of the animals were in conformity with standards as outlined by the National Academy of Science [15,16,17].

2.3 Acetaminophen and Vitamin E

Acetaminophen and alpha tocopherol acetate (vitamin E) were purchased from Carbosynth Company, Unit 8 and 9, Old Station Business PK, Compton, RG20 SNE United Kingdom. Other reagents and chemicals used in this study were of analytical grade and purest quality.

2.4 Experimental Design

2.4.1 Determination of median lethal dose (LD₅₀) of *Garcinia kola* seed extract

The 15 rats were divided into five groups comprising of three animals each. Different doses of the *Garcinia kola* seed extract were given to each group. Group 1 received 1000 mg and groups 2, 3, 4 and 5 were given 2000 mg, 3000 mg, 4000mg and 5000mg respectively. The doses were given by oral gavage in a constituted form. As stated in OECD/OCDE, [18], the doses

were expressed in terms of extract weight/animal weight based on the recommendation of (OECD-OCDE 425 Guide). The rats were observed within 24hours and symptoms of toxicity and mortality in each group were recorded and LD₅₀ were calculated using arithmetic method of Karbar [19]. The toxicity of the *Garcinia kola* was evaluated by different characteristic signs for the rat which can be retained as toxicity elements of the extract. Using the oral route, the animals shared dose-dependent signs of toxicity, ranging from lack of appetite, depression immobility and respiratory distress to death.

2.4.2 Treatment regimen

Group 1 (Control Group): Made up of rats with average weight of 120 g and receiving normal feed and distilled water orally. Isotonic 0.9% NaCl was given on the 8th day.

Group 2 (Acetaminophen - induced only): This is the hepatotoxicity control group, received normal feed and distilled water for 7 days orally and intoxicated with 800 mg acetaminophen intraperitoneally on the 8th day.

Group 3 (high dose *Garcinia kola* extract +Acetaminophen): This group was pretreated with 800 mg/kg of *Garcinia kola* seed extract for 7 days orally and then intoxicated with 800 mg acetaminophen intraperitoneally on the 8th day.

Group 4 (low dose *Garcinia kola* extract +Acetaminophen): This group was pretreated with 100 mg/kg of *Garcinia kola* seed extract for 7 days orally and then intoxicated with 800 mg acetaminophen intraperitoneally on the 8th day.

Group 5 (low dose *Garcinia kola*+ low dose vitamin E+ Acetaminophen): This group was pretreated with 100 mg/kg of *Garcinia kola* seed extract mixed with 25 mg/kg of vitamin E for 7 days orally and then intoxicated with 800 mg acetaminophen intraperitoneally on the 8th day.

Group 6 (high dose *Garcinia kola*+ high dose vitamin E+ Acetaminophen): This group was pretreated with 800 mg/kg of *Garcinia kola* seed extract mixed with 50 mg/kg of vitamin E for 7 days orally and then intoxicated with 800 mg acetaminophen intraperitoneally on the 8th day.

Group 7 (Low dose vitamin E + acetaminophen): This group receives only 25 mg/kg of vitamin E pretreatment for 7 days orally and then intoxicated with 800 mg acetaminophen intraperitoneally on the 8th day.

Group 8 (High dose vitamin E + acetaminophen): This group receives only 50 mg/kg of vitamin E pretreatment for 7 days orally and then intoxicated with 800 mg acetaminophen intraperitoneally on the 8th day.

A modified pretreatment plan in line with the recommendation of Ganie [20] was used. Intraperitoneal administration of the acetaminophen was done on the 8th day respectively according to the method of [21]. The animals were fasted overnight, sacrificed under chloroform anesthesia [22], blood was collected for biochemical and oxidative stress analysis by cardiac puncture into a plain tube, allowed to clot and serum obtained by centrifuging at 3000 rpm for 10 mins in a Wisperfuge centrifuge (Model 1384, Tamsa Holland). The right sided liver was removed and fixed in 10% formal saline for histopathological studies. The sections were subsequently prepared and stained with haematoxylin and eosin (H&E) for examination.

2.5 Methods

The activities of alanine amino transferase and aspartate aminotransferase was determined by the method of Reitman [23]. Alkaline phosphatase (ALP) activity was determined using the colorimetric method as described by Chuku [24]. The Bromocresol green (BCG) method as reported by Doumas [25] was used to determine the albumin concentration in the samples. Biuret method was used to determine the level of total protein in the sample according to the method of Flack & Woollen [26]. Malondialdehyde (MDA, was estimated using spectrophotometric method [27], in which the reaction between thiobarbituric acid and thiobarbituric reactive substances (TBARS) like Malondialdehyde produces a fluorescent red derivative that can be examined using the spectrophotometer. Determination of Catalase activity [28] by the spectrophotometric method. The estimation of the Superoxide Dismutase activity was determined using auto-oxidation method [29]. The activity of glutathione peroxidase enzyme in the serum was determined according to the method of Rotruck [30].

2.5.1 Fixation and tissue processing

The formalin preserved hepatic tissue samples of the albino rats and controls were processed in an automated tissue processor (Tissue-tek VIP-5, from SAKURA). The processing consisted of an initial 2 step fixation comprising tissue immersion

in 10% buffered formalin for two hours each, followed by removal of fixative in distilled water for 30 minutes. Dehydration was then carried out by running the tissues through a graded series of alcohol (70%, 90%, and 100%). The tissue was initially exposed to 70% alcohol for 30 minutes followed by 90% alcohol for 1 hour and then two cycles of absolute alcohol, each for one hour. Dehydration was then followed by clearing the samples in several changes of xylene. It consisted of tissue immersion for an hour in a mixture comprising 50% alcohol and 50% xylene, followed by pure xylene for one and a half hour. Samples were then impregnated with molten paraffin wax, then embedded and blocked out. Paraffin sections (4–5 μ m) were stained with hematoxylin and eosin, the conventional staining technique. The hepatic tissue was evaluated for any alterations in the architecture, portal or lobular inflammation, sinusoidal dilatation and congestion along with presence of granulomas, degeneration, necrosis, cellular infiltrations and fatty change.

2.5.2 Procedure for haematoxylin and eosin (H&E) staining

The tissue section from the respective liver organs was dewaxed in xylene 1 and 11, hydrated in descending grades of alcohol. Then rinsed in tap water before staining in Ehrlich's haematoxylin solution for 5-10 minutes. It was then rinse in water for a few seconds, and then differentiated in 1% acid alcohol with continuous agitation for 10 to 15 seconds. It was later blued in scott tap water for 5minutes. Then the counter stain, 1% aqueous eosin solution was applied for the next 2 mins. It was rinsed in running tap water for 30 seconds and then dehydrated in ascending grades of alcohol. It was cleared in xylene 1 and 11 and then mounted with a mountant (DPX) for viewing with the microscope.

2.5.3 Quality control measures

External quality control sera were assayed along with the analyses. Standard operating procedures were duly adhered to while carrying out the analysis. Good laboratory practices were observed while conducting the test.

2.6 Statistical Analysis

Values are presented as means and standard deviation, One Way Analysis Of Variance (ANOVA) followed by the Tukey Multiple comparison test using the Graph Pad Instant

Version 3.10.12 bit for Windows was used to compare the mean values among the groups to check for statistical differences. Values were considered significant at $p < 0.05$.

3. RESULTS

3.1 LD₅₀ Determination

The results gotten from the acute toxicity investigation of the aqueous extract of *Garcinia kola* seed on the rats are shown in Table 1.

3.2 Hepatic Results

The results for the analysis of the hepatic parameters in the 1st week are shown in Table 2. In the first week (Table 2), comparison of the means of all the groups using analysis of variance (ANOVA) shows significant difference ($p < 0.05$, $F = 1081$) in the means of ALT between the treatment groups. The comparison of the means of groups 2-8 with the mean of the control using Tukey Multiple Comparison Test shows significant difference ($p < 0.05$). The level of alanine amino transferase (ALT) of the toxicity group (group 2) was significantly increased ($p < 0.05$) when compared with the control (group 1) while there was a significant decrease ($p < 0.05$) in groups 3 (pretreated with the high dose of *Garcinia Kola* extract), Group 4 (low dose of *Garcinia Kola*), 5 & 6 (pretreated with a low or high dose of the combined form), 7 & 8 (pretreated with a low and high dose of Vitamin E) were significantly increased ($p < 0.05$) when they were all compared with the control though the mean values in the groups 3-8 were all decreased when compared with the toxicity group (group 2).

It was also observed when comparing the result from the low dose of *Garcinia Kola* with that of Vitamin E (group 4 versus 7) that the ALT levels were significantly different likewise in the comparison of high doses of *Garcinia Kola* with that of Vitamin E (groups 3 versus 8), the ALT levels were significantly different ($p < 0.05$).

The means of aspartate aminotransferase (AST) levels of all the groups in the 1st week were compared together using ANOVA and found to be significantly different ($p < 0.05$, $F = 349.9$). The comparison of the means of groups 2-8 against the control was done using the Tukey Multiple

Comparison Test. Results shows that groups 2, 4, 5, 6, 7, 8 were significantly increased ($p < 0.05$) when compared with the control (group 1). Though the AST levels in groups 4, 5, 6, 7, 8 are decreased when compared to the toxicity group (group 2). Group 3 shows an insignificant increase in AST levels in group 2, 3, 4, 5, 6, 7 and 8 when compared with the control.

Comparing the AST levels in groups 4 and 7 showed a significant difference ($p < 0.05$) while the comparison between group 3 and 8 also showed a significant difference ($p < 0.05$) in the levels of AST in the 1st week.

The means of alkaline phosphatase (ALP) levels of all the groups in the 1st week were compared together using ANOVA and found to be significantly different ($p < 0.05$, $F = 3022$). The comparison of the means of groups 2-8 against the control was done using the Tukey Multiple Comparison Test. The Alkaline phosphatase (ALP) levels in the 1st week was significantly increased ($p < 0.05$) in groups 2, 5, 6 & 8 while in groups 3 & 4, it was significantly decreased ($p < 0.05$) when compared with the control. Meanwhile in groups 7, the ALP level was insignificantly increased when compared to the control.

Also, there was a significant difference ($p < 0.05$) of ALP levels when comparing groups 4 and group 7. This significant difference was also observed when comparing ALP levels in groups 3 and 8 in the 1st weeks as reflected in Table 2.

The mean value of total protein of all the groups in the 1st week were compared together using ANOVA and found to be significantly different ($p < 0.05$, $F = 89.78$). The comparison of the means of groups 2-8 against the control was done using the Tukey Multiple Comparison Test. Total protein levels in the first week showed significant decrease ($p < 0.05$) in groups 2, 5, 6 and an insignificant decrease ($p > 0.05$) in groups 4, 7, 8 when compared with the control meanwhile in group 3, there was a significant ($p < 0.05$) increase in the protein level.

Comparison of protein level between groups 4 & 7 in the 1st week showed insignificant difference ($p > 0.05$) while the comparison of protein level between groups 3 & 8 in the 1st week was significantly different ($P < 0.05$).

Table 1. Acute toxicity (LD₅₀) investigation of aqueous extract of *Garcinia kola* seed

Group	Medium	Quantity in grams	Neurological deficit	Reflexes	No of death (mortality)	Feeding	Lethal concentration	Safe Dose
GROUP I	aqueous	1	Normal, stable.	Active tail & whisker movement noticeable	0	Normal	2 g and/or greater	1 g/kg. b.w. and/or less.
Group II	„	2	Normal, stable.	Active tail & whisker movement noticeable	1	Normal		
Group III	„	3	Sub-normal, stable,	Less tail & whisker movement	1	little		
Group IV	„	4	Restless, confused, anorexic	Less tail & whisker movement	1	less		
Group V	„	5	Withdrawal behaviour, sluggish	No locomotion, tail & whisker movement lost	all	none		

The means of albumin levels of all the groups in the 1st week were compared together using ANOVA and found to be significantly different ($p < 0.05$, $F = 4.464$). The comparison of the means of groups 2-8 against the control was done using the Tukey Multiple Comparison Test. The albumin levels in groups 2 and 6 were significantly decreased ($p < 0.05$) while there was an insignificant decrease ($p > 0.05$) observed in groups 3, 4, 5, 7 & 8 when compared with the control in the 1st week.

Comparison between groups 4 and groups 7 in the 1st week showed an insignificant difference in the albumin levels. Likewise, there was an insignificant difference ($p > 0.05$) when the albumin levels in group 3 was compared with that of group 8 as shown in Table 2.

3.3 Results of Oxidative Stress Parameters

The means of malondialdehyde (MDA) of all the groups in the 1st week were compared together using ANOVA and found to be significantly different ($p < 0.05$, $F = 412.7$). The comparison of the means of groups 2-8 against the control was done using the Tukey Multiple Comparison Test. The malondialdehyde (MDA) levels showed significant increase ($p < 0.05$) in groups 2, 3, 4, 5, 6, 7, & 8 when compared with the control group in the first week and the levels in the pretreated groups (3, 4, 5, 6, 7, 8) were all reduced compared to the toxicity group (group 2) showing recovery of the system as a result of the antioxidant pretreatments.

The comparison of MDA levels between groups 3 and 8, groups 4 and 7 was insignificantly different ($p > 0.05$) in the 1st week as reflected in Table 3.

The means of superoxide dismutase (SOD) of all the groups in the 1st week were compared together using ANOVA and found to be significantly different ($p < 0.05$, $F = 2246$). The comparison of the means of groups 2-8 against the control was done using the Tukey Multiple Comparison Test. The Superoxide Dismutase (SOD) levels in the 1st week showed a significant decrease ($p < 0.05$) in groups 2, 4, 5, & 6 and a significant increase ($p < 0.05$) in group 3 & 8. There was an insignificant decrease ($p > 0.05$) observed in group 7 when all the mean values were compared with the control.

The comparison of SOD levels between group 4 and 7 likewise in groups 3 and 8 in the 1st week were significantly different ($p < 0.05$).

The means of catalase (CAT) of all the groups in the 1st week were compared together using ANOVA and found to be significantly different ($p < 0.05$, $F = 251.5$). The comparison of the means of groups 2-8 against the control was done using the Tukey Multiple Comparison Test. The catalase level (CAT) in the 1st week were significantly decreased ($p < 0.05$) in groups 2, 3, 4, 5, 6, 7, & 8 when compared with the control. The comparison of the catalase (CAT) levels between group 4 and 7 and groups 3 and 8 in the 1st week was significantly different ($p < 0.05$).

The means of glutathione peroxidase (GPX) of all the groups in the 1st week were compared together using ANOVA and found to be significantly different ($p < 0.05$, $F = 1726$). The comparison of the means of groups 2-8 against the control was done using the Tukey Multiple Comparison Test. The glutathione peroxidase (GPX) levels in the 1st week showed significant decrease ($p < 0.05$) in group 2 and 6 and a significant increase in group 8 meanwhile there

Table 2. Mean ± SD of hepatic parameters in albino rats after 7 days pretreatment

Groups	ALT (U/L ± SD)	AST (U/L ± SD)	ALP (U/L ± SD)	Protein (g/L ± SD)	Albumin (g/L ± SD)
1(Control)	34.2 ± 1.64 ^{bc}	52.6 ± 1.52 ^{bc}	47.4 ± 1.14 ^{bc}	66.6 ± 2.41 ^b	36.6 ± 1.95
2	98.6 ± 0.89 ^a	100.6 ± 1.14 ^a	138.4 ± 2.30 ^a	54.6 ± 1.95 ^a	29.2 ± 2.28 ^a
3	28.0 ± 1.23 ^{ab}	56.0 ± 1.23 ^b	34.4 ± 1.14 ^{ab}	71.6 ± 1.52 ^{ab}	35.0 ± 0.71
4	44.0 ± 1.41 ^{ac}	64.0 ± 2.12 ^{ac}	44.8 ± 1.30 ^{ac}	64.4 ± 2.97	33.6 ± 0.89
5	77.6 ± 1.95 ^a	91.6 ± 1.67 ^a	90.6 ± 1.34 ^a	51.6 ± 1.14 ^a	32.8 ± 4.09
6	75.2 ± 2.78 ^a	90.8 ± 2.28 ^a	97.6 ± 1.52 ^a	46.0 ± 1.41 ^a	30.6 ± 1.95 ^a
7	51.6 ± 1.52 ^{ac}	89.2 ± 0.84 ^{ac}	48.6 ± 0.89 ^c	64.0 ± 1.41	34.4 ± 2.61
8	50.6 ± 0.89 ^{ab}	82.2 ± 4.44 ^{ab}	50.8 ± 1.64 ^{ab}	66.4 ± 2.97 ^b	34.8 ± 3.96
F value	1081	349.9	3022	89.78	4.464
p value	<0.0001	<0.0001	<0.0001	<0.0001	<0.0001

Values are presented in mean ± SD. n = 5. $p < 0.05$. ALT-Alanine aminotransferase, AST-Aspartate aminotransferase, ALP- Alkaline Phosphatase. . a- significantly different from control. b- Means with same letter are significantly different. c- Mean values with same letter are significantly different

Table 3. Mean ± SD of oxidative parameters in albino rats after 7 days pretreatment

Groups	MDA (µmol/ml ± SD)	Catalase (U/mg ± SD)	SOD (µg/ml ± SD)	Glutathione peroxidase (µg/ml ± SD)
1(Control)	2.35 ±0.02	0.47 ±0.02 ^{bc}	7.54 ±0.06 ^{bc}	29.67 ±0.41 ^b
2	6.84 ±0.36 ^a	0.15 ±0.01 ^a	4.89 ±0.06 ^a	20.57 ±0.02 ^a
3	2.84 ±0.17 ^a	0.38 ±0.01 ^{ab}	8.25 ±0.15 ^{ab}	29.70 ±0.01 ^b
4	2.87 ±0.14 ^a	0.29 ±0.01 ^{ac}	5.64 ±0.04 ^{ac}	29.79 ±0.17
5	4.85 ±0.06 ^a	0.23 ±0.02 ^a	3.45 ±0.07 ^a	29.76 ±0.05
6	3.85 ±0.10 ^a	0.24 ±0.02 ^a	4.36 ±0.05 ^a	28.95 ±0.05 ^a
7	2.82 ±0.18 ^a	0.37 ±0.02 ^{ac}	7.53 ±0.02 ^c	29.58 ±0.03
8	2.87 ±0.01 ^a	0.44 ±0.02 ^{ab}	7.85 ±0.15 ^{ab}	30.72 ±0.21 ^{ab}
F value	412.7	251.5	2246	1726
p value	<0.0001	<0.0001	<0.0001	<0.0001

Values are presented in mean ± SD. n= 5. p< 0.05 . MDA- Malondialdehyde, SOD-Superoxide Dismutase
a- significantly different from control. *b*- Mean values with same letter are significantly different. *c*- Mean value with same values are significantly different

was no significant increase (p>0.05) in groups 3, 4, & 5 and insignificant decrease in group 7 when all these mean values were compared with the control. This is shown in Table 3.

The comparison of GPX levels between group 4 and 7 in the 1st week was insignificantly different (p>0.05) while in group 3 and 8 in the 1st week it was significantly different (p<0.05).

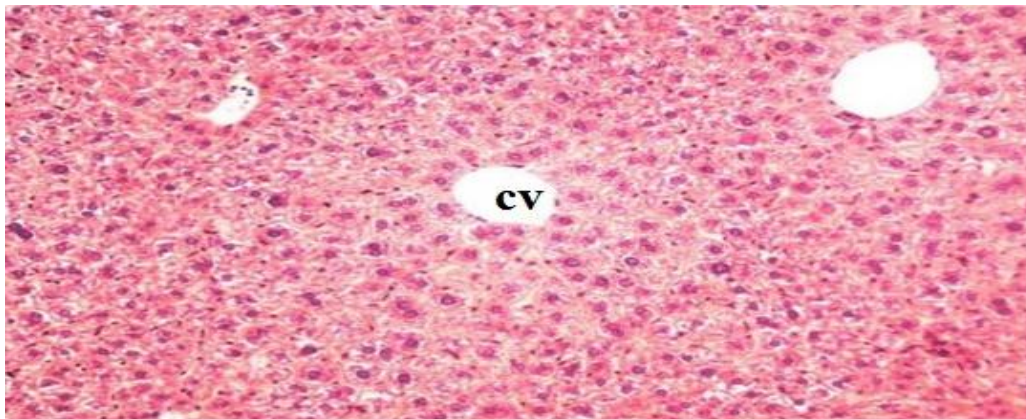


Plate 1. Photo micrographic slide of liver organ of group 1 control 1 (distilled water + isotonic 0.9% NaCl) H & E X100. CV-Normal central vein and normal hepatic lobule

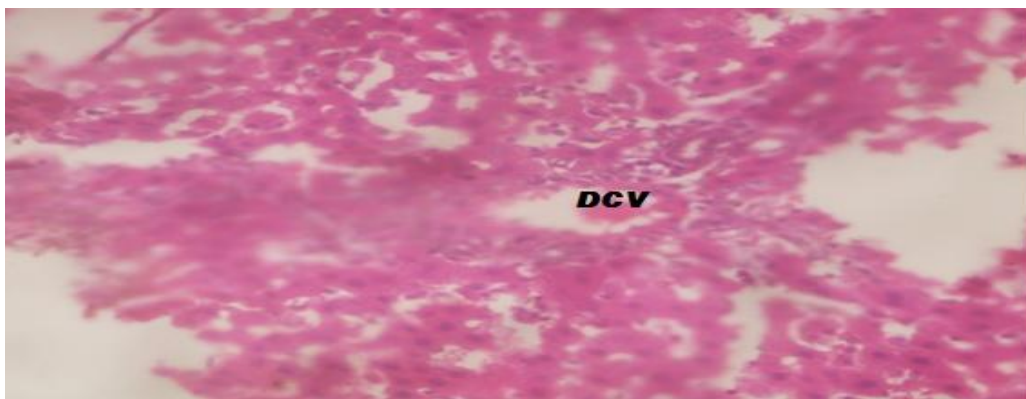


Plate 2. Photo micrographic slide of liver organ of Group 2 (Acetaminophen-induced toxicity only) H & E X100. DCV –markedly dilated central vein filled with red blood cells, surrounded by swollen hepatocytes. Field showing a disrupted hepatic matrix

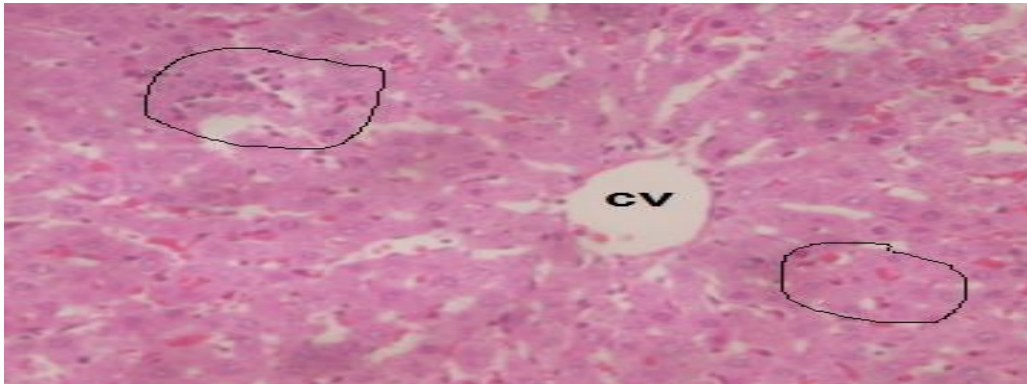


Plate 3. Photo micrographic slide of liver organ of Group 3 (high dose *Garcinia kola*+ acetaminophen) H & E X100. Cellular architecture stilled savagely preserved even with signs of sinusoidal haemorrhage evident with presence of blood and cellar debris in the recovering portal traid.CV-central vein

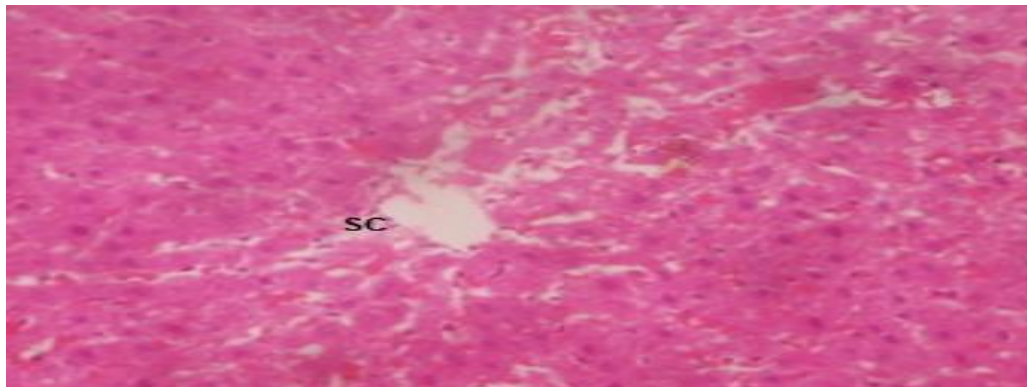


Plate 4. Photo micrographic slide of liver organ of Group 4 (low dose *Garcinia kola*+ acetaminophen) H & E X100. Very slow process of cellular matrix salvage. Aggregate of cells despite degeneration suggestive of hepatic response. SC- Breakdown of limiting space of disse

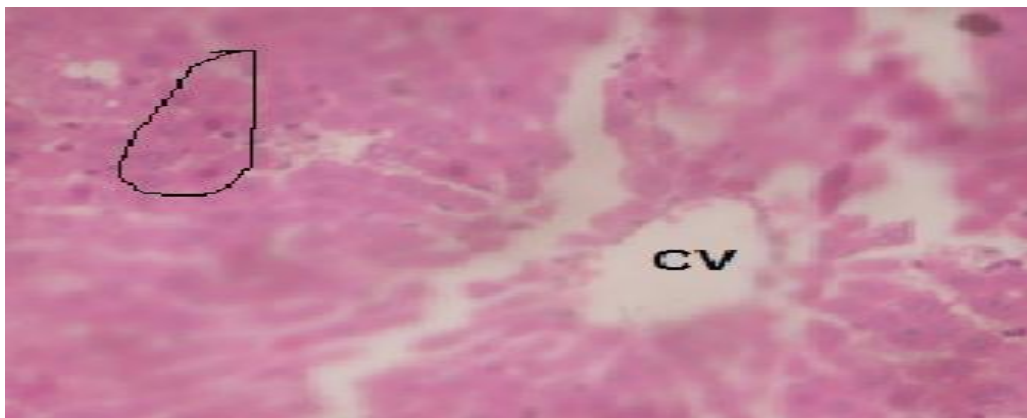


Plate 5. Photo micrographic slide of liver organ of Group 5 (low dose *Garcinia kola* + low dose vitamin E +acetaminophen) H & E X100. CV- Central vein. Pale area of cell showing a phase of recovery with the presence of nuclear cells

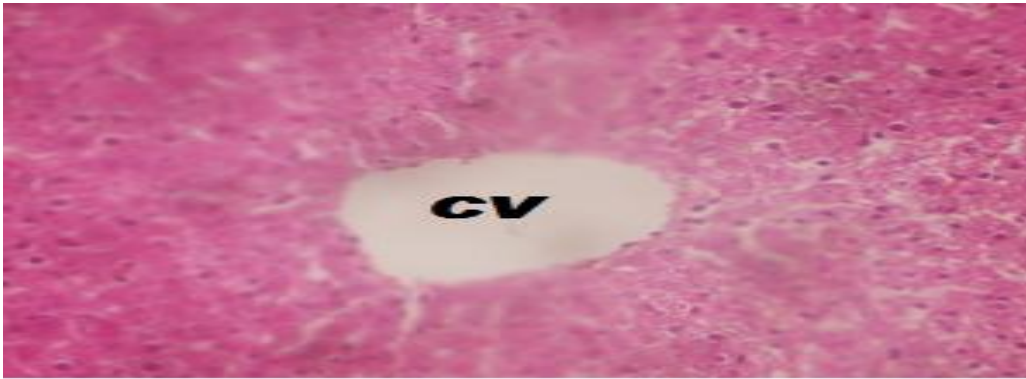

Plate 6. Photo micrographic slide of liver organ of Group 6 (high dose *Garcinia kola* + high dose vitamin E + acetaminophen) H & E X100. CV-Central vein. Emerging healthy sinusoidal matrix evident with nuclear cells

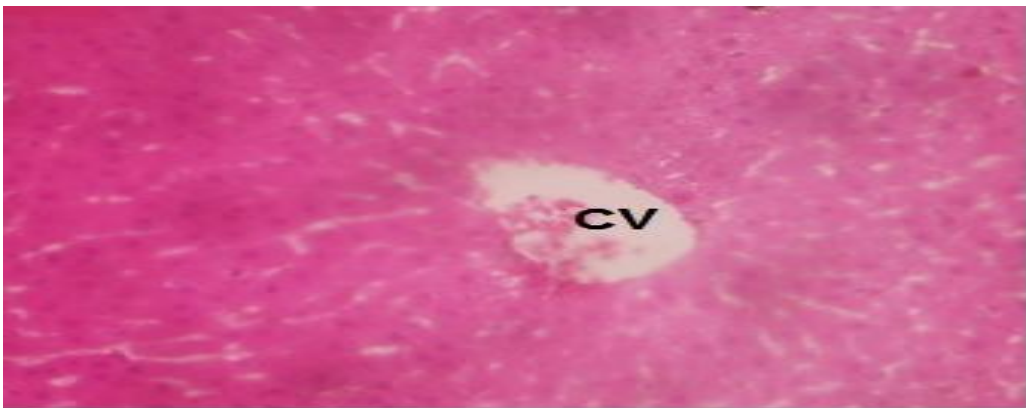


Plate 7. Photo micrographic slide of liver organ of Group 7 (low dose vitamin E + acetaminophen) H & E X100. Disrupted cellular matrix and architectural integrity.CV partially filled with cellular debris

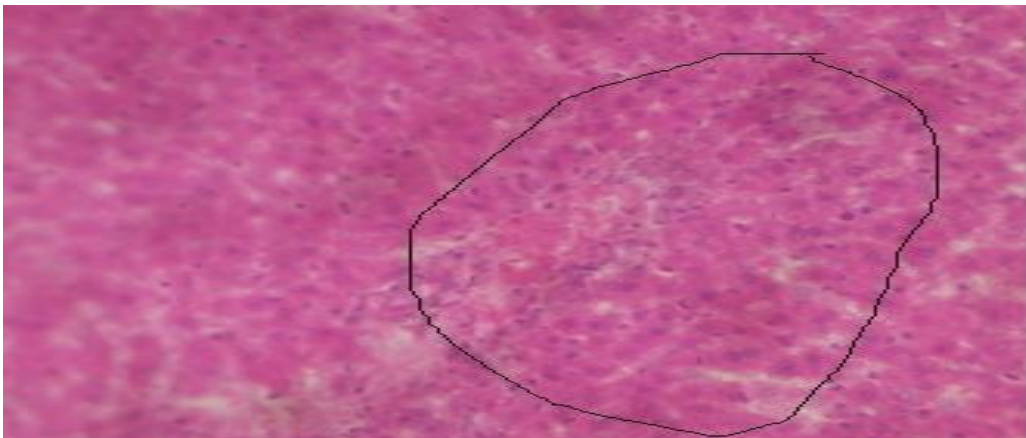


Plate 8. Photo micrographic slide of liver organ of Group 8 (high dose vitamin E + acetaminophen) H & E X100.Presence of Erythroid and myeloid in the matrix precursors showing signs of cellular breakdown –slow recovery process

3.4 Histopathological Examination of Liver Tissues

The photo micrographic slides of liver organ are shown from Plates 1 to 8 for the different groups involved in the experiment study.

4. DISCUSSION

The liver is a vital organ of immense importance. It is involved in the maintenance of metabolic functions and detoxification of exogenous and endogenous agents like the exposure to drugs. This study demonstrates that acetaminophen causes detrimental changes in the liver by inducing toxicity upon the administration of 800mg of it to the rats on the 8th day after pretreatment. This agrees with work done by [31,32] on the ability of acetaminophen to induce hepatotoxicity. It is well established that high dose of acetaminophen induces the production of a highly toxic metabolite, N-acetyl P-benzoquinone imine through the cytochrome P450 pathway leading to hepatic damages. In this state, it is expected that there will be significant increase in the serum levels of AST, ALT, ALP and a decrease in the total protein and albumin levels [33]. This pattern of results were observed in the group 2 treated rats which corroborates the work of Rajesh [34] indicating a damage to the liver cells. The increased levels of the serum enzymes are indication of cellular leakage and loss of functional integrity of the cell membrane of the liver [35]. This is because the amino transferase (ALT and AST) are localized in the periportal hepatic cells while the alkaline phosphatase is seen in cells lining the biliary duct of the liver. These enzymes are seen in the hepatic damages due to the loss of hepatocyte structural integrity and leakage hence known as biomarkers of hepatic damage [36].

The decrease in the protein and albumin level is an indication that the synthetic function of the liver might have been affected since the evaluation of albumin level is a good index for assessing the metabolic ability of the liver [37].

From Table 2, there was a significant difference ($p < 0.05$) when all the mean values of the respective groups were compared with the control. In groups 3 and 4 results, a remarkable hepato -protective activity against the hepatotoxicity was observed as seen from the levels of the hepatic biomarkers (ALT, ALP & AST). This is in agreement with the work done by

Eminedoki [1]. The reversal of the increased serum enzymes by the *Garcinia kola* extract may be due to the prevention of the leakage of the intracellular enzymes since *Garcinia kola* is known to be a membrane stabilizer as stated by Iwu [38]. This finding is also in agreement with the study of [39] which stated that serum levels of the hepatic enzymes return to normal with the healing of hepatic parenchyma and the regeneration of hepatocytes. Rajesh [34] also states that the efficacy of any hepatoprotective drug is based on either its capacity to reduce the harmful effect or the ability to restore the cells to normal hepatic physiology after an attack by a toxin.

Braide [40] also posit that the anti-hepatotoxicity of *Garcinia kola* is found in the biflavonoid compound of the kolaviron. It might also be deduced that the decreased levels seen in the hepatic enzymes in groups 3 and 4 could be as a result of the antioxidant effect of *Garcinia kola* [41]. It is also documented that the rich content of biflavonoid in *Garcinia kola* are effective inhibitors of lipid peroxidation hence they scavenge the free radicals and promote antioxidative activities [42].

Pretreatment with vitamin E (50 mg/kg, 25 mg/kg) respectively as seen in groups 7 and 8 ameliorated the effect of acetaminophen toxicity. This was also reflected in the decrease levels of the hepatic enzymes as compared with the acetaminophen toxicity group. There was an increased level of protein and albumin level as seen in Table 2. This change might be attributed to the antioxidant effect of vitamin E. Vitamin E has been shown in several studies to be an inhibitor of lipid peroxidation processes as reported by [42].

In groups 5 and 6, there were evidence of salvage of the hepatic organs as seen in the result shown in Table 2. From the result, the synergetic effect of this combination was not as promising as when you look at the protective potential exhibited when *Garcinia kola* seed extract and vitamin E were administered singly irrespective of their doses. So it shows that pretreating with either *Garcinia kola* or vitamin E is more advisable than combining.

Malondialdehyde (MDA), Catalase (CAT), Superoxide Dismutase (SOD) and glutathione peroxidase (GPX) were used to analyse the oxidative stress level in the study as shown in Table 3 which is reflected by the elevation in the

level of malondialdehyde and the decreased in the levels of superoxide dismutase, catalase and glutathione peroxidase. Acetaminophen administration resulted in a significant surge of oxidative stress [43] which obviously proved that lipid peroxidation occurred producing reactive free radicals that weaken the antioxidant defense system as reflected in group 2.

Glutathione peroxidase and superoxide dismutase have been quantified as measures of antioxidant capabilities [44] hence their values as seen in this study. However, this study demonstrates that acetaminophen toxicity resulted in an overt oxidative stress mechanism. When a condition of oxidative stress is established, the defense capacities against reactive oxygen species become insufficient [45].

The decreased levels of superoxide dismutase, catalase and glutathione peroxidase in group 2 further established the toxic potential of acetaminophen and these findings agree with report of antioxidant enzyme depletion in acetaminophen intoxication as studied by Morakinye [46]. Also the increased level of MDA in this study agrees with previously reported study of Devaki [47].

Pretreatment of the albino rats with *Garcinia kola* prior to acetaminophen administration caused a marked decrease in the levels of MDA and an increase in SOD, CAT and GPX levels. This suggests that the seeds of *Garcinia kola* may be protective against acetaminophen induced oxidative stress as seen in groups 3 and 4 results. The enzyme antioxidant defense systems are the natural protector against lipid peroxidation. Reactive oxygen species are known to induce the oxidation of membrane lipid with the subsequent production of MDA, a specific biomarker of lipoperoxidation [48]. SOD accelerates dismutation and scavenges cytotoxic superoxide radicals into hydrogen peroxides. It is the major defense for aerobic cells in fighting and withstanding the toxic effect of these radicals. This is achieved by converting the radicals into water and oxygen. It also prevents the generation of hydroxyl radicals thereby protecting the cellular constituents from oxidative damage thus offering the first line of protection to the cells [49]. This finding is suggestive of the ability of *Garcinia kola* to boost the production of the natural antioxidant (SOD, CAT, and GPX) within the system of the experimental animals and also an evidence of the quenching capacity of the free radicals. This is in agreement with earlier findings

of Adedera [50] which states that the seeds of *Garcinia kola* possess antilipoperoxidative effect, a proof of its antioxidative properties inhibiting lipid peroxidation as seen in the MDA result for groups 3 and 4 (table 3). The reduction in MDA level prior to pretreatment with *Garcinia kola* is in accordance with the findings of Wegwu [51] which stated that *Garcinia kola* seed possesses natural antioxidants which can salvage cells from free radical damage.

Vitamin E pretreated rats had significantly decreased MDA level and increased antioxidant enzymes (SOD, CAT, & GPX) almost near the control level as seen in the group 7 and 8 (Table 3). This further corroborates with findings by Tain [52] that vitamin E is capable of scavenging free radicals derived from acetaminophen toxicity. Thus proving vitamin E to exhibit protective role as a better antioxidant. In groups 5 and 6, it was observed those protective tendencies might have been exhibited as a result of the pretreatment as further shown by the decreased in malondialdehyde levels as compared to the toxicity group and the increased enzymatic antioxidant levels.

Histological findings revealed no distortion on the architecture of the liver in the control rats (Plate 1). It was also observed that massive vacuoles filled with fluids and dark spots, cellular infiltrations indicative of inflammation was the case in group 2 (toxicity group) as reflected in Plate 2. It is well established that acetaminophen administration causes an acute centrilobular necrosis in rats with an eosinophilic cytoplasm [53]. The pigmentation observed might be as a result of the stain haematoxylin and eosin as reported by Garba [54]. It is known that the cytochrome P450 system is found around the zone 3-centrilobular (Z3) region hence the production and localization of the toxic metabolite which induces the hepatic necrosis around the region [55]. This finding is in consistent with reported observation [56]. This further agrees with reports that cells generally dies as a result of necrosis when exposed to toxins, noxious agent or injury [57].

The effect of *Garcinia kola* extract and vitamin E to protect hepatocellular injury was further confirmed by histopathological observations which suggest protective potentials against membrane attack and destruction of the membrane permeability and fragility thus decreasing the leakage of the liver biomarkers into the circulation. The reduction of the severity

of acetaminophen damage was seen in the liver of groups that received a pretreatment with *Garcinia kola* or vitamin E. Salvage of the liver cells were evident with the presence of binucleated cells, reduced vacuoles, emergence of immune cells to fight upon provocation and clearing of debris from the portal tract as seen in the plates except in Plates 5 & 6 where much repairs were not seen even when these agents are combined.

5. CONCLUSION

The effect of the combined form of *Garcinia kola* seed extract and vitamin E pretreatment in this study was not synergistic. However, further studies should be carried out to evaluate the biochemical interactions between *Garcinia kola* seed aqueous extract and vitamin E. *Garcinia kola* seed and vitamin E may be potential therapeutic and curative agents because they showed the abilities to ameliorates acetaminophen induced toxicity and oxidative stress in albino rats.

ETHICAL APPROVAL

As per international standard written ethical approval has been collected and preserved by the author(s).

COMPETING INTERESTS

Authors have declared that no competing interests exist.

REFERENCES

1. Eminedoki DG, Uwakwe AA, Ibe GO. Protective effect of *Garcinia kola* seed and honey mixture against paracetamol induced hepatotoxicity in rats. Nigerian Journal of Biochemistry and Molecular Biology. 2010;25(2):1-8.
2. Adegboye MF, Akinpelu DA, Okoh AI. The bioactive and phytochemical properties of *Garcinia kola* (Heckel) seed extract on some pathogens. African Journal of Biotechnology. 2008;7(11):3934-3938.
3. Traber MG, Atkinson J. Vitamin E, antioxidant and nothing more. Free Radical Biology & Medicine. 2007;43(1):4-15.
4. Pawan K, Verma M, Sultana R, Raina S, Praws S, Pandita NJ, Arshad HM. Hepatoprotective effects of *Ageratum canyzoides* L on biochemical indices induced by acetaminophen toxicity in wistar rats. Journal of Applied Pharmaceutical Science. 2013;3(4):523-527.
5. Lead AM, Begona Ruiz-Larrea M, Martinez R, Lacort M. Cytoprotective actions of estrogens against tert-butyl hydroperoxide-induced toxicity in hepatocytes. Biochemical Pharmacology. 1998;56:1463-1469.
6. Lewerenz V, Hanett S, Nasterska C, El-Balay C, Rohrdanz E, Kahl R. Antioxidant protect primary rate *Hepatocytes cutures* against acetaminophen-induced DNA strand breaks but not against acetaminophen-induced cytotoxicity. Toxicology. 2003;191:179-187.
7. Sin B, Wai M, Tatunchak T, Motov SM. The use of intravenous acetaminophen for acute pain in the emergency department. Academic Emergency Medicine. 2016;23:543-53.
8. Nelson SD. Molecular mechanisms of the hepatotoxicity caused by acetaminophen. Seminar on liver Disease. 1990;10:267-278.
9. Dahlin DC, Miwa GT, Lu AY, Nelson SD. N-acetyl-P-benzoquinone imine: A cytochrome P-450-mediated oxidation product of acetaminophen. Proceedings of the National Academic of Science. 1984; 81:1327-1331.
10. Vermeulen NPE, Bessems JGM, Vande Streat R. Molecular aspects of paracetamol induced hepatotoxicity and its mechanism based prevention. Drug Metabolism and Revolution. 1992;24:367-457.
11. Hinston JA, Reid AB, McCullough SS, James LP. Acetaminophen-induced hepatotoxicity: Role of metabolic activation, reactive oxygen/ nitrogen species, and mitochondrial permeability transition. Drug Metabolism Revolution. 2004;36:805-822.
12. Tiwari A. Imbalance in antioxidant defense and human diseases: Multiple approach of natural antioxidants therapy. Current Science. 2001;81:1179-1187.
13. Karber G. Beitrag zur kollektiven Behandlung pharmakologischer Reihenversuche. Achives of Experimental Pathology and Pharmacokology. 1931;162: 480-483.
14. Lorke D. A new approach to practical acute toxicity testing. Archives of Toxicology. 1983;54:275-287.

15. PHS. Public health service policy on humane care and use of laboratory animals. Publication of the Department of Health and Human Services. National Institute of Health. Office of Laboratory Animal Welfare; 2015.
16. ILAR. Guideline for the care and use of laboratory animal. 8th edition. National academic Press. Washington D.C; 2011.
17. OLAW. Institution Animal care and use committee Guidebook. 2nd edition NIH publication. Bethesda. 2002;1-230.
18. OECD/OCDE. Guideline for testing of chemical, acute oral toxicities, up and down Procedure. 2001;425:1-26.
19. Dede EB, Kagbo HD, Igbigbi PS. Determination of LD₅₀ value of Metekelfin in rats. Journal of Science and Meta Science. 1997;1:1-7.
20. Ganie SA, Zargar A, Mosood MA. Hepatoprotective and antioxidant activity of rhizome of *Podophyllum hexandrum* against carbon tetrachloride-induced hepato-toxicity in rats. Biomedical Environmental Science. 2013;26(3):209-221.
21. Ven Kumar MR, Latha MS. Hepatoprotective effect of the methanolic extract of *Curculigo orchoides* in CCL₄-treated male rats. Indian Journal of Clinical Biochemistry. 2002;17-2:80-87.
22. AVMA. Guidelines for euthanasia of animals. American Veterinary Medical Association. 2013;1-102.
23. Reitman S, Frankel S. A colorimetric method for determination of serum glutamate oxaloacetate and glutamic pyruvate transaminase. American Journal of Clinical Pathology. 1957;28:56-58.
24. Chuku LC, Uwakwe AA, Chinaka NC. Liver enzymes in normal and sickle cell subjects. Journal of Natural Science Research. 2012;2(7):1-4.
25. Doumas BT, Watson WA, Biggs HG. Albumin standards and the measurement of Serum albumin with bromocresol green. Clinica Chimica Acta. 1971;31:87-96.
26. Flack CP, Wollen JW. Prevention of interference by Dextran with Biuret-type Assay of serum proteins. Clinical Chemistry. 1984;30(4):559-561.
27. Ohkawa H, Ohishi N, Yagi K. Assay for lipid peroxides in animal tissues by thiobarbituric acid reaction. Analytical Biochemistry. 1979;95(2):351-358.
28. Aebi H. Aebi H (ed) Catalase *in vitro*. Methods in Enzymology. 1984;105:121-126.
29. Misra HP, Fridovich I. The role of superoxide anion in the antioxidation of epinephrine and a simple assay of Superoxide Dismutase. Journal of Biological Chemistry. 1972;247:3170-3175.
30. Rotruck JT, Pope AL, Ganther HE, Swanson AB, Hafeman DG, Hoekstra WG. Selenium: Biochemical role as a component of *Glutathione peroxidase*. Science. 1973;179(4073):588-590.
31. Akintowa A, Essien AR. Protective paracetamol-induced hepatotoxicity in rats. Journal of Ethnopharmacology. 1990;29: 207-211.
32. Lancaster EM, Hiatt JR, Zarrinpar A. Acetaminophen hepatotoxicity: An updated review. Archives of Toxicology. 2015;89(2): 193-197.
33. Rakapoor B, Venugopal Y, Anbu J, Harikrishinah N, Gobinath M, Ravichandran V. Protective effect of *Phyllanthus polyphyllus* on acetaminophen induced hepatotoxicity in rats. Pakistan Journal of Pharmaceutical Science. 2008; 21(1):57-62.
34. Rajesh SV, Rajkapoor B, Kumar S, Raju K. Effect of *Clausena dentate*(willd) M. roem. against paracetamol induced hepatotoxicity in rats. Pakistan Journal of Pharmacological Science. 2009;22(1):90-93.
35. Moore M, Thor H, Moore G, Nelson S, Moldeus P, Orrenius S. The toxicity of acetaminophen and N. acetyl P-benzoquinoneimine in isolated hepatocyte associated with the depletion and increased cytosolic Ca²⁺. Journal of Biological Chemistry. 1985;260:13035-13040.
36. Kaplan MM. Laboratory tests. In: Schiff L., Schiff, E.R eds. Disease of the liver, 7th edition. Philadelphia, J. B. Lippincott; 1993.
37. Jesse B. Animal anatomy and physiology. USA, Reston publishing Company; 1982.
38. Iwu MM, Igboko OA, Tempesta MS. Biflavonoids constituents of *Garcinia kola* root. Fitoterapia. 1990;61:178-181.
39. Thabrew M, Joice P. A comparative study of the efficacy of *Pavetta indica* and *Osbeckia octanda* in the treatment of liver dysfunction. Planta Medicine. 1987;53: 239-241.
40. Braide VP. Antihepatotoxic biochemical effects of kolaviran, a biflavonoid of

- Garcinia kola seeds. Phytotherapy Research. 1991;5:35-37.
41. Omaye K, Erifeta OG, Uzunmangho SE, Sunday JJ, Kazeem AO. Evaluation of hypoglycemic and antioxidative properties of aqueous extract of *Garcinia kola* seeds in wistar rats. Current Research Journal of Biological Science. 2011;3(4):326-329.
 42. Terashima K, Takawa Y, Niwa M. Powerful antioxidative agents based on Garcinonic acid from *Garcinia kola*. Biorganic Medicinal Chemistry. 2002;10(16):19-1625.
 43. Tribble DL, Aw TY, Jones DP. The pathophysiological significance of lipid peroxidation in oxidative cell injury. Hepatology. 1987;7:377-387.
 44. Edwin HO, Keyvan KG, Chia-Chi L, Ravi B, Gemma AF. Biological markers of oxidative stress: Applications to cardiovascular research and practice. Redox Biology. 2013;1:483-491.
 45. Sies H. Oxidative stress, strategies of antioxidant defense. European Journal of Biochemistry. 1993;215:213-219.
 46. Morakinyo AO, Iranloye BO, Oyelowo OT, Nnaji J. Antioxidative and hepatoprotective effect of beta carotene on acetaminophen induced liver damage in rats. Biology and Medicine. 2012;4(3):134-140.
 47. Devaki T, Raghavendran HRB, Sathivel A. Hepatoprotective nature of seaweed alcoholic extract on acetaminophen induced hepatic oxidative stress. Journal of Health Science. 2004;50:42-46.
 48. Michel F, Bonnefont-Rousselot D, Mas E, Draï J, Therond P. Biomarkers of lipid peroxidation: Analytical aspects. Annals of Biological Clinics. 2008;66:605-620.
 49. Johnson F, Giulivi C. Superoxide dismutases and their impact upon human health. Molecular Aspects of Medicine. 2005;26:340-352.
 50. Adedara IA, Awogbindin IO, Anamelechi JP, Farombi EO. *Garcinia kola* seed ameliorates renal, hepatic and testicular oxidative damage in streptozotocin – induced diabetic rats. Pharmaceutical Biology. 2015;53(5):695-704.
 51. Wegwu, MO, Didia BC. Hepatoprotective effect of *Garcinia kola* seed against hepatotoxicity induced CCl₄ in rats. Biochemistry. 2007;19(1):17-21.
 52. Tain YL, Freshour G, Dickalova A, Griendlira K, Baylis C. Vitamin E reduces glomerulosclerosis, restores renal neuronal NOS and suppresses oxidative stress in the 5/6 nephrectomized rat. American Journal of Physiological Renal Physiology. 2007;292(5):F1404-F1410.
 53. Boyd EM, Bereckzky GM. Liver damage from paracetamol. British Journal of Pharmacology. 1996;26:606.
 54. Garba AM, Mohammed B, Garba SH, Numan AL, Dalar BM. Effect of honey and aloe vera extraction on ibuprofen induced liver damage in rats. Journal of Pharmacy and Biological Science. 2012;3:2278-3008.
 55. Chung YH, Kim JA, Song BC, Koh MS, Lee HS, Yu E, Lee YS, Su DJ. Centrilobular hepatic necrosis, isocitrate dehydrogenase as a marker of centrilobular model of rats. Journal of Gastroenterology and Hepatology. 2001; 16: 328-332.
 56. Oliveira FA, Chaves MH, Almeida FRC, Lima RCP, Silva RM, Maia JL, Brito GA, Santos FA, Rao VS. Protective effect of a- and b- amyirin, a triterpene mixture from protium heptaphyllum (Aubl.) Trunk wood resin against acetaminophen-induced liver injury in mice. Journal of Ethnopharmacology. 2005;98:103-108.
 57. Eroschenko VP. Atlas of histology with functional correlations (9th edition), Lippincott, Williams and Wilkins publishers; 2000.

© 2019 Waribo et al.; This is an Open Access article distributed under the terms of the Creative Commons Attribution License (<http://creativecommons.org/licenses/by/4.0>), which permits unrestricted use, distribution, and reproduction in any medium, provided the original work is properly cited.

Peer-review history:

The peer review history for this paper can be accessed here:
<http://www.sdiarticle4.com/review-history/51592>